



Immunoexpression of HPV 16/18 E6 and E7 oncoproteins in high-grade cervical squamous intraepithelial lesions in HIV-positive women

L.C. Rodrigues¹, N.M. de Gois Speck¹, G.R. de Azevedo Focchi², M.A. Schmidt¹, R.M. Marques³ and J.C. Lascasas Ribalta¹

¹Núcleo de Prevenção de Doenças Ginecológicas, Departamento de Ginecologia, Universidade Federal de São Paulo, São Paulo, SP, Brasil

²Departamento de Patologia, Universidade Federal de São Paulo, São Paulo, SP, Brasil

³Disciplina de Oncologia Ginecológica, Departamento de Ginecologia, Universidade Federal de São Paulo, São Paulo, SP, Brasil

Corresponding author: G.R. de Azevedo Focchi

E-mail: gustavo.focchi@terra.com.br

Genet. Mol. Res. 15 (1): gmr.15017220

Received August 15, 2015

Accepted October 28, 2015

Published February 19, 2016

DOI <http://dx.doi.org/10.4238/gmr.15017220>

ABSTRACT. The aim of this study was to assess the immunoexpression of human papillomavirus genotypes 16 and 18 (E6 and E7) oncoproteins in cervical high-grade squamous intraepithelial lesions (HSIL) of human immunodeficiency virus (HIV)-positive women. These results were also compared to the persistence and/or recurrence of lesions after loop electrosurgical excision procedure. Cervical samples from 158 patients were divided into three groups according to the presence or absence of HSIL in women who were or were not HIV-positive. By using the tissue microarray technique, immunohistochemistry was performed to analyze the expression of HPV 16/18 E6 and E7 oncoproteins. Cervical samples from 95 HIV-positive women and 63 HIV-negative women were studied. A statistically significant difference was found in the immunoexpression of E6 and E7 oncoproteins in samples from HIV-positive women with HSIL and

that of women with non-neoplastic tissue ($P < 0.001$). There was also a statistically significant correlation between the immunoeexpression of E6 ($P = 0.012$) and E7 ($P < 0.001$) oncoproteins in lesion persistence among HIV-positive women. Within the limitations of this study, the immunoeexpression of HPV 16/18 E6 and E7 oncoproteins may have prognostic value regarding lesion persistence in HIV-positive women.

Key words: Human immunodeficiency virus; E6 oncoprotein; E7 oncoprotein; Human papillomavirus 16/18; High-grade squamous intraepithelial lesions

INTRODUCTION

The correlation between the persistence of oncogenic human papillomavirus (HPV) infection, particularly HPV 16/18, with cervical high-grade squamous intraepithelial lesions (HSIL) and invasive squamous cell carcinoma led to the development of functional studies on E6 and E7 HPV oncogenes (Doeberitz, 2002). The inactivation of p53 and retinoblastoma proteins by the HPV 16/18 E6 and E7 oncoproteins induces proliferation, immortalization and malignant transformation of infected cells (Boulet et al., 2007).

Based on common risk and behavioral factors, HPV induced cervical neoplasia and immunodeficiency virus (HIV) infection both feature characteristics of sexually transmitted diseases (Maiman et al., 1990; Garzetti et al., 1995; Pantanowitz and Michelow, 2011). Multiple epidemiological studies related the incidence and severity of HPV infection, as well as genital neoplasia, with immune status. These parameters are elevated in immunodeficient women, especially those infected with HIV, and the cervix is the most common site involved (Garzetti et al., 1995; Kobayashi et al., 2002; Moscicki et al., 2004).

This study aimed to assess the expression of HPV 16/18 E6 and E7 oncoproteins in cervical HSILs of both HIV-positive and -negative women using immunohistochemistry. These results were correlated to the persistence and recurrence of lesions after loop electrosurgical excision procedure (LEEP).

MATERIAL AND METHODS

Patient samples

In an observational study, fragments of uterine cervix from colposcopic guided biopsies and LEEP were obtained from 186 women who were treated at the Lower Genital Tract Pathology Clinic in Núcleo de Prevenção de Doenças Ginecológicas (NUPREV) from the General Gynecology Area of Escola Paulista de Medicina at Universidade Federal de São Paulo (EPM-UNIFESP). Formalin-fixed and paraffin-embedded tissue samples were obtained from the archives of the Pathology Department of EPM-UNIFESP, which supplied a cession declaration concerning the relevant samples. The project was approved by the Research Ethics Committee of EPM-UNIFESP (approval certificate No. CEP 0811/07 and was reassessed in April 2012).

One hundred and ten samples were obtained from HIV-positive women from the Immunological Deficiency Control Center, Infections and Parasitary Diseases of EPM-UNIFESP, and 76 samples were obtained from immunocompetent women assisted at NUPREV from 1997 to 2010. The samples were distributed into three groups: group 1 was HIV-positive women with

HSIL; group 2 was HIV-positive women without cervical neoplasia; and group 3 was HIV-negative women with HSIL.

Post-treatment follow-up consisted of colposcopic examination with cytological sampling and a colposcopic guided biopsy when indicated every 6 months for a 2 year period. Persistent disease was defined as the presence of cyto-colpo-histopathological abnormality in a 2-year interval after LEEP treatment. Recurrence was defined as the occurrence of HPV infection or neoplasia after negative cyto-colpo-histopathological results.

In order to assess many different samples with small aliquots of primary antibody, leading to a saving in reagents and a shorter time for analysis, the samples were homogenized and the tissue microarray technique (TMA) was used with a fixed-base device and 1.5-mm diameter needles (Kononen et al., 1998). Two blocks were built containing cylinders with 1.7 mm between their centers. One block had 110 cylinders, containing the sections of histopathological material from HIV-positive patients, and the other had 76 cylinders, containing sections from HIV-negative patients. Then, 4- μ m thick sections were cut and adhered to silanized slides. Among them, three slides were selected for hematoxylin-eosin staining for evaluation of the sections and to assess tissue loss.

Immunohistochemistry

The immunohistochemical reactions were performed at the Immunopathology and Special Techniques Laboratory of the Pathology Department of EPM-UNIFESP.

The slides were treated with 3-aminopropyltriethoxysilane and left for 24 h at 60°C in an oven to improve adhesion of the tissue to the slide. Then, paraffin was removed with xylol at room temperature for 30 minutes. The slides were hydrated with ethanol in decreasing concentrations (100, 95, 80, and 70%) for 30 s each and washed with water. Antigenic retrieval was performed in a pressure cooker for 4 min followed by washing (2X) in 50% hydrogen peroxide for 10 min. Then, slides were washed with water and immersed in phosphate buffered saline (PBS; 10 mM, pH 7.4). The slides were incubated with primary antibody against E6 or E7 (monoclonal mouse anti-HPV16/18 antibody E6, Fullmoon, Sunnyvale, CA, USA, 1:300 dilution, and monoclonal mouse anti-HPV16/18 antibody E7, Fullmoon, 1:150 dilution) in a wet chamber at 4°C for 18 h. Following this, they were washed in PBS (pH 7.4) and incubated with secondary antibody (labeled streptavidin-biotin; Dako, CA, USA) for 60 min.

After reaction amplification with the catalyzed signal amplification kit (Dako) for anti-E6 and -E7 antibodies, specimens were washed and developed in substrate solution, comprised of 3,3-diaminobenzidine tetrahydrochloride (1 mL:50 μ L; Sigma-Aldrich Chemical, St. Louis, MO, USA), 600 μ L hydrogen peroxide 30 vol, 100 mL PBS, and 1 mL dimethylsulfoxide, for 5 min at 37°C, followed by counterstaining with Harris hematoxylin. Samples were then immersed in ammonia water, washed with water, dehydrated in absolute alcohol, and immersed in xylol. Slides were finally assembled with coverslips using Entellan Merck mounting media (Darmstadt, Germany). A HPV 16-positive HSIL sample was used as an external positive control.

Interpretation of E6 and E7 immunostaining

An optical microscope (Olympus model BX 40, Tokyo, Japan) was used for the evaluation of the slides. In each case, all microscopic fields (400X) were analyzed, with variable representation of epithelial and stromal components. Squamous epithelial cells with brownish nuclear and/or cytoplasmic staining were considered positive. For the evaluation of E6 and E7 immunoeexpression,

we used an arbitrary score system of four categories: negative (less than 10% of stained cells); slightly positive (+, 10 to 40%); moderately positive (++, 41 to 70%); and absolutely positive (+++, 71 to 100%) of stained cells (Ressler et al., 2007). For the purposes of statistical analysis, the immunoexpression results were qualified as either negative or positive (which included all +, ++ and +++ scores).

Statistical analysis

For the comparison of qualitative variables (e.g., frequencies and proportions), the chi-square test with continuity correction was used. To analyze recurrence of epithelial lesions in the groups, the Fisher exact test along with the chi-square test with continuity correction were used. A level of 5% ($P \leq 0.05$) was considered significant.

RESULTS

After TMA construction and immunohistochemical reactions for E6 and E7 oncoproteins, a loss of 28 cases occurred, corresponding to nearly 15% of samples. The remaining 158 cases were distributed into three groups, as follows: group 1 = HIV-positive women with HSIL (61 samples); group 2 = HIV-positive women without cervical neoplasia (34 samples); and group 3 = HIV-negative women with HSIL (63 samples). The patients ranged in age from 22 to 63 years, with an average age of 35.1 years in Group 1. In group 2, the patients were between 21 and 62 years old, with an average age of 40 years and, in group 3, patients ranged in age from 17 to 70 years, with an average age of 33.7 years.

According to the Centers for Disease Control and Prevention classification system for the evaluation of immunodeficiency based on CD4 cell counts, there was a statistically significant difference ($P = 0.0152$, data not shown) between the two HIV-positive groups. Women with HSIL were more likely to have low CD4 cell counts (lower than 200 cells/mm³) than women without neoplasia.

Due to the importance in identifying the specific types of HPV involved in causing cervical cancer and its precursor lesions, the expression of HPV 16/18 E6 and E7 oncoproteins in HIV-positive women with HSIL (group 1) were analyzed using immunohistochemistry and compared to the results of HIV-positive women without neoplasia (group 2). A comparison was then made with the results of women with HSIL who were negative for HIV (group 3). In the comparison between groups 1 and 2, a statistically significant difference was found regarding the immunoexpression of E6 and E7 oncoproteins (Figures 1 and 2; $P < 0.001$). The expression of E6 and E7 oncoproteins was similar in groups 1 and 3, where women were positive for HSIL (Figures 1 and 3), and no statistically significant difference was found for E6 ($P = 0.830$) or E7 ($P = 0.565$) between the groups (Tables 1 and 2).

According to the chi-square test with continuity correction, a statistically significant difference was found in the positive immunoexpression of E6 ($P = 0.012$) and E7 ($P < 0.001$) regarding lesion persistence in groups 1 and 3. The HIV-positive women in group 1 had a higher prevalence of lesion persistence than the HIV-negative women in group 3 (Tables 3 and 4). When correlating lesion recurrence with the immunoexpression of E6 and E7 in groups 1 and 3, no statistically significant difference was found regarding the positive expression of E6 ($P = 0.495$) or E7 ($P = 0.633$) (data not shown).

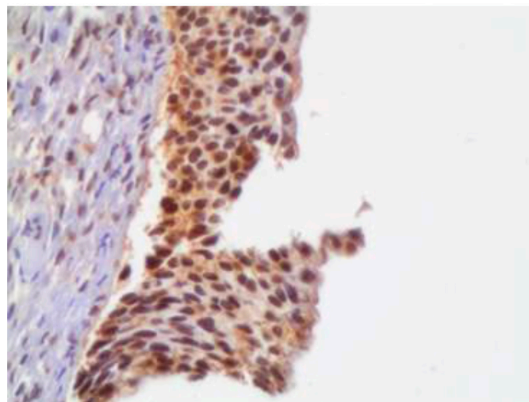


Figure 1. Photomicrograph of uterine cervix of a HIV-positive patient with high-grade squamous intraepithelial neoplasia showing presence of brownish nuclear staining for E7 in 70 to 100% of neoplastic cells (400X).

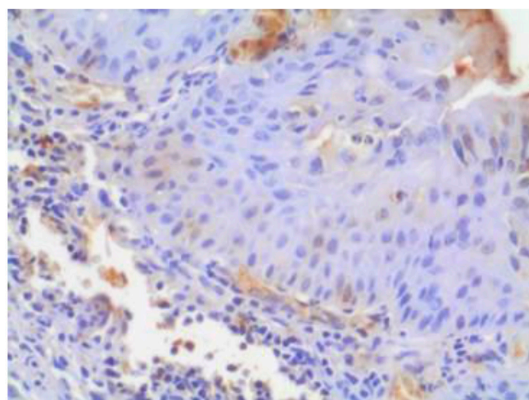


Figure 2. Photomicrograph of uterine cervix of a HIV-positive patient with non-neoplastic squamous epithelium showing absence of nuclear staining for E6 (400X).

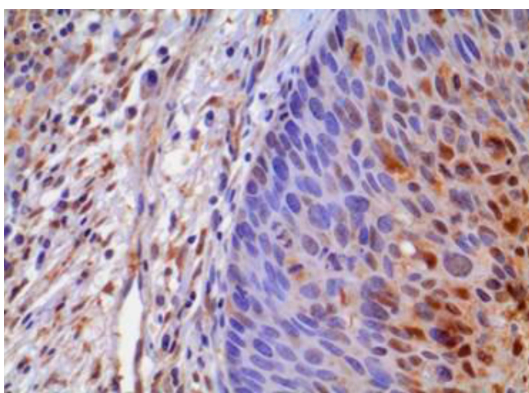


Figure 3. Photomicrograph of uterine cervix of a HIV-negative patient with high-grade squamous intraepithelial neoplasia showing presence of brownish nuclear staining for E6 in 10 to 40% of the neoplastic cells (400X).

Table 1. Comparative analysis of HPV 16/18 E6 oncoprotein immunoeexpression.

E6 oncoprotein	Group 1		Group 2		Group 3	
	N	(%)	N	(%)	N	(%)
NEG	24	(39.3)	27	(79.4)	27	(42.9)
POS	37	(60.7)	7	(20.6)	36	(57.1)
Total	61	(100.0)	34	(100.0)	63	(100.0)

Group 1 x Group 2: chi-square test with continuity correction; $\chi^2 = 12.531$; $P < 0.001$. Group 1 x Group 3: Chi-square test with continuity correction; $\chi^2 = 0.046$; $P = 0.830$. Group 1 = HIV-positive women with HSIL; Group 2 = HIV-positive women without neoplasia; Group 3 = HIV-negative women with HSIL; NEG = negative; POS = positive.

Table 2. Comparative analysis of HPV 16/18 E7 oncoprotein immunoeexpression.

E7 oncoprotein	Group 1		Group 2		Group 3	
	N	(%)	N	(%)	N	(%)
NEG	11	(18.0)	30	(88.2)	8	(12.7)
POS	50	(82.0)	4	(11.8)	55	(87.3)
Total	61	(100.0)	34	(100.0)	63	(100.0)

Group 1 x Group 2: chi-square test with continuity correction; $\chi^2 = 41.044$; $P < 0.001$. Group 1 x Group 3: Chi-square test with continuity correction; $\chi^2 = 0.331$; $P = 0.565$. Group 1 = HIV-positive women with HSIL; Group 2 = HIV-positive women without neoplasia; Group 3 = HIV-negative women with HSIL; NEG = negative; POS = positive.

Table 3. Correlation between positive HPV 16/18 E6 oncoprotein immunoeexpression and lesion persistence.

Persistence	E6 positive samples	
	Group 1	Group 3
	N (%)	N (%)
No	15 (48.4)	29 (80.6)
Yes	16 (51.6)	7 (19.4)
Total	31# (100.0)	36 (100.0)

Chi-square test with continuity correction; $\chi^2 = 6.285$; $P = 0.012$. Group 1 = HIV-positive women with HSIL; Group 3 = HIV-negative women with HSIL; NEG = negative; POS = positive; #six patients with E6 immunoeexpression without follow-up.

Table 4. Correlation between positive HPV 16/18 E7 oncoprotein immunoeexpression and lesion persistence.

Persistence	E7 positive samples	
	Group 1	Group 3
	N (%)	N (%)
No	16 (39.0)	45(81.8)
Yes	25 (61.0)	10 (18.2)
Total	41# (100.0)	55 (100.0)

Chi-square test with continuity correction; $\chi^2 = 16.767$; $P < 0.001$. Group 1 = HIV-positive women with HSIL; Group 3 = HIV-negative women with HSIL; NEG = negative; POS = positive. #Nine patients positive for E7 immunoeexpression without follow-up.

DISCUSSION

Anti-E6 and -E7 HPV16/18 antibodies were used in this study to assess the expression of E6 and E7 oncoproteins in HIV-positive women using immunohistochemistry analysis. With the construction of the TMA, immunohistochemical reactions for HPV16/18 E6 and E7 oncoproteins were considered adequate for evaluation in 158 (85%) samples. The excluded cases corresponded to section losses or non-representation of squamous epithelium. Our results are in accordance with other similar studies (Schneider, 2006).

We noticed a wide variation in the immunostaining pattern of HPV oncoproteins in our samples. Thus, all positive scores were combined into a single category and compared to the negative results. The analysis of E6 and E7 immunoexpression results among HIV-positive women with HSIL (group 1) and without neoplasia (group 2) revealed a statistically significant difference for both proteins between the two groups ($P < 0.001$). Group 1 samples had a higher percentage of cells positive for E6 and E7 immunoexpression than group 2. These results are in accordance with previous studies (Nyagol et al., 2006). Similar to the findings of Ressler et al. (2007) in HIV-negative women, our results in HIV-positive women suggest that the expression of the E7 oncoprotein can be considered as a surrogate marker for premalignant cervical epithelial lesions. Even though HPV genotyping was not done in our samples, high levels of E7 immunoexpression was observed.

When comparing immunoexpression of E6 and E7 in HIV-positive women with HSIL (group 1) and HIV-negative women with HSIL (group 3), no statistical difference was found between the two groups. This could be due to HPV DNA already being integrated in the host genome, as is commonly seen in cervical high-grade squamous intraepithelial neoplasia; thus, the HPV oncoproteins would be expressed and HIV positivity does not modify HPV oncogene expression. Further studies assessing the relationship between HPV E6 and E7 immunoexpression patterns and the time interval for lesion progression to cervical cancer should be performed.

The correlation of positive immunoexpression of E6 and E7 oncoproteins with lesion recurrence was similar between groups 1 and 3, with no statistically significant difference. That is to say, once the intraepithelial lesion was eradicated by surgical treatment with free margins and negative post-treatment examinations, the chance of recurrence was similar between HIV-positive and HIV-negative women. Regarding immunopositivity for HPV E6 and E7 oncoproteins, HIV-positive women presented higher indexes of lesion persistence than HIV-negative women. These findings reinforce the importance of positive expression of E6 and E7 oncoproteins in intraepithelial lesion persistence and cervical cancer development. Perhaps the greatest difficulty in achieving effective immunity against HPV is the ability of this virus to evade immune surveillance, delaying immune system activation, coupled with the extensive number of HPV genotypes. Studies have shown that HIV-positive patients are infected with a greater diversity of high-risk and low-risk HPV subtypes, with a higher frequency of oncogenic subtypes, compared to HIV-negative patients. This increases their susceptibility to the development of cancers of the lower genital tract, particularly in the cervix (Pantanowitz and Michelow, 2011).

One of the limitations of this study is that no HPV genotyping was carried out. While a higher prevalence of HPV 16 and 18 infections have been found, the expression of E6 and E7 oncoproteins of other HPV genotypes was possibly not detected, which could generate false-negative results. On the other hand, it is also possible that the antibody used in this study could cross react with other HPV genotypes, which could also generate false positive results. Further studies are to be carried out with a larger number of cases while also evaluating the specific HPV genotype related to the intraepithelial lesion. This should confirm our results of the immunoexpression of

HPV 16/18 E6 and E7 oncoproteins in HIV-positive women.

Within the limitations of this study, the immunoeexpression of HPV 16/18 E6 and E7 oncoproteins may have prognostic value regarding lesion persistence in HIV-positive women.

Conflicts of interest

The authors declare no conflict of interest.

ACKNOWLEDGMENTS

The authors thank Joaquim Soares de Almeida for his assistance with the TMA construction.

REFERENCES

- Boulet G, Horvath C, Vanden Broeck D, Sahebali S, et al. (2007). Human papillomavirus: E6 and E7 oncogenes. *Int. J. Biochem. Cell Biol.* 39: 2006-2011. <http://dx.doi.org/10.1016/j.biocel.2007.07.004>
- Garzetti GG, Ciavattini A, Butini L, Vecchi A, et al. (1995). Cervical dysplasia in HIV-seropositive women: role of human papillomavirus infection and immune status. *Gynecol. Obstet. Invest.* 40: 52-56. <http://dx.doi.org/10.1159/000292302>
- Kobayashi A, Darragh T, Herndier B, Anastos K, et al. (2002). Lymphoid follicles are generated in high-grade cervical dysplasia and have differing characteristics depending on HIV status. *Am. J. Pathol.* 160: 151-164. [http://dx.doi.org/10.1016/S0002-9440\(10\)64359-3](http://dx.doi.org/10.1016/S0002-9440(10)64359-3)
- Kononen J, Bubendorf L, Kallioniemi A, Bärnlund M, et al. (1998). Tissue microarrays for high-throughput molecular profiling of tumor specimens. *Nat. Med.* 4: 844-847. <http://dx.doi.org/10.1038/nm0798-844>
- Maiman M, Fruchter RG, Serur E, Remy JC, et al. (1990). Human immunodeficiency virus infection and cervical neoplasia. *Gynecol. Oncol.* 38: 377-382. [http://dx.doi.org/10.1016/0090-8258\(90\)90077-X](http://dx.doi.org/10.1016/0090-8258(90)90077-X)
- Moscicki AB, Ellenberg JH, Crowley-Nowick P, Darragh TM, et al. (2004). Risk of high-grade squamous intraepithelial lesion in HIV-infected adolescents. *J. Infect. Dis.* 190: 1413-1421. <http://dx.doi.org/10.1086/424466>
- Nyagol J, Leucci E, Onnis A, De Falco G, et al. (2006). The effects of HIV-1 Tat protein on cell cycle during cervical carcinogenesis. *Cancer Biol. Ther.* 5: 684-690. <http://dx.doi.org/10.4161/cbt.5.6.2907>
- Pantanowitz L and Michelow P (2011). Review of human immunodeficiency virus (HIV) and squamous lesions of the uterine cervix. *Diagn. Cytopathol.* 39: 65-72. <http://dx.doi.org/10.1002/dc.21364>
- Ressler S, Scheiden R, Dreier K, Laich A, et al. (2007). High-risk human papillomavirus E7 oncoprotein detection in cervical squamous cell carcinoma. *Clin. Cancer Res.* 13: 7067-7072. <http://dx.doi.org/10.1158/1078-0432.CCR-07-1222>
- Schneider V (2006). Tissue microarrays for testing molecular biomarkers of cervical intraepithelial neoplasia: feasibility study. *Acta Cytol.* 50: 123-128. <http://dx.doi.org/10.1159/000325919>
- von Knebel Doeberitz M (2002). New markers for cervical dysplasia to visualise the genomic chaos created by aberrant oncogenic papillomavirus infections. *Eur. J. Cancer* 38: 2229-2242. [http://dx.doi.org/10.1016/S0959-8049\(02\)00462-8](http://dx.doi.org/10.1016/S0959-8049(02)00462-8)