



Craniocervical decompression with duraplasty and cerebellar tonsillectomy as treatment for Chiari malformation-I complicated with syringomyelia

C.S. Bao, L. Liu, B. Wang, X.-G. Xia, Y.J. Gu, D.J. Li, S.L. Zhan, G.L. Chen and F.B. Yang

Department of Neurosurgery, The Affiliated Hospital of Luzhou Medical College, Luzhou, Sichuan Province, China

Corresponding author: F.B. Yang
E-mail: fubingyangcn@126.com

Genet. Mol. Res. 14 (1): 952-960 (2015)
Received May 15, 2014
Accepted October 23, 2014
Published February 3, 2015
DOI <http://dx.doi.org/10.4238/2015.February.3.2>

ABSTRACT. This study aimed to investigate the therapeutic effects of craniocervical decompression with duraplasty and cerebellar tonsillectomy for the treatment of Chiari malformation-I with syringomyelia (CM I-SM). From January 2005 to December 2011, 127 patients with CM I-SM underwent craniocervical decompression with duraplasty and cerebellar tonsillectomy and the therapeutic effects of these surgeries were evaluated using Tator scores. No patient in this study died or showed disease deterioration after the surgery. Re-examination by magnetic resonance imaging (MRI) showed that the cisterna magna was obviously larger after the operation in all but one patient. Moreover, syringomyelia (SM) was reduced in 76 patients. CM I-SM symptoms disappeared or decreased in 112 patients after following discharge. Follow-up was conducted in 84 of the patients and 79 of these patients exhibited improved symptoms. A second MRI re-examination showed that the cisterna magna was successfully constructed in 44

patients; 42 of these patients showed further eliminated or obviously reduced SM. Craniocervical decompression with duraplasty and cerebellar tonsillectomy achieved favorable therapeutic effects. Thus, craniocervical decompression with duraplasty and cerebellar tonsillectomy is a rational surgical approach with beneficial clinical effects. The proposed approach may have useful applications in the treatment of CM I-SM.

Key words: Chiari malformation; Syringomyelia; Surgery; Duraplasty; Craniocervical decompression; Cerebellar tonsillectomy

INTRODUCTION

Chiari malformations (CMs), also known as cerebellar tonsil herniation malformations, are congenital malformations characterized by a reduced posterior cranial fossa volume and downward displacement of the cerebellar tonsil into the spinal canal. CMs may be complicated by multiple malformations, such as platybasia, basilar invagination, atlanto-occipital fusion, and syringomyelia (SM). Moreover, SM is the most common complication of CMs.

In the late 19th century, the Austrian pathologist Chiari classified CMs into four types: I-IV (Chiari, 1891, 1895). Type I displays downward displacement of the cerebellar tonsil and medial portions of the inferior cerebellar lobes accompanying the medulla oblongata into the cervical spinal canal. In 1894, the German pathologist Julius Arnold described this disease in more detail (Arnold, 1994). In 1907, the disease was formally known as the Arnold-Chiari malformation (Schwalbe and Gredig, 1907). However, an increasing number of scholars named this disease the Chiari malformation (Tarieeo and Melo, 2008; Williams, 2008).

Simon introduced the term hydromyelia to designate dilation of the ependymal canal by cerebrospinal fluid and used the term SM to refer to cavities that developed independently of the central canal of the spinal cord (Simon, 1875). SM and hydromyelia are widely acknowledged to be different stages of the same pathological process. However, Finlayson stated that hydromyelia is a congenital disturbance resulting from incomplete regression of the fetal ependymal canal, whereas SM can be either congenital or acquired (Finlayson, 1981). In China, the high prevalence of CM I-SM has been reported by many authors (Zhang et al., 2000, 2004; Huang et al., 2005), but its underlying causes remain unclear.

Recent research has focused on the pathogenesis, diagnosis, and operational treatment of CM I-SM. In this study, we investigated the therapeutic effects of craniocervical decompression with duraplasty and cerebellar tonsillectomy in the treatment of CM I-SM.

MATERIAL AND METHODS

General information

A total of 127 patients (57 males, 70 females) participated in this study. All patients underwent craniocervical decompression with duraplasty and cerebellar tonsillectomy surgeries from January 2005 to December 2011 in the Department of Neurosurgery at the Affiliated Hospital of Luzhou Medical College. Diagnosis of CM I-SM in all patients was confirmed by MRI and patients exhibiting atlanto-axial dislocation and occipitocervical instability were ex-

cluded. The disease course of patients ranged from 2 weeks to 12 years, with an average course of 3.4 years. The age of the patients ranged from 15 to 65 years, with an average age of 42.3 years. Twelve patients were under 25 years, 68 patients were between 25 and 45 years, and 29 patients were over 40 years of age. Most patients were between 25 and 45 years old (62.4%).

Clinical symptoms

Symptoms relating to damage to the central canal of the spinal cord was found in 82 patients. Separable sensory disorders of the limb or body and muscle atrophy of the hand or upper extremity were found in 37 patients. Symptoms of nerve root irritation, including pain and burning sensations in the neck, shoulders, back, or upper extremities, were found in 45 patients. Symptoms of the lower cranial nerves and the cerebellum, including unsteady gait, were found in 24 patients, nystagmus in 14 patients, difficulty in swallowing in 12 patients, and hoarseness in 12 patients. Symptoms relating to damage to the pyramidal tract, including tendon-mediated increases in muscle tone, hyperreflexia, and muscle weakness, were found in 39 patients. Symptoms of increased intracranial pressure, including headaches, vomiting, and papilledema were found in 10 patients (Table 1).

Table 1. Preoperative and postoperative symptoms/signs in 127 CM I-SM Patients*.

Symptom/Sign	Preoperation status	Postoperation status (discharge)		
	No. of Patients	Improved	Unchanged	Worse
Sensory disorders	37	33	4	0
Pain and burning sensations	45	44	1	0
Gait problems and gait ataxia	24	22	3	0
Lower cranial nerve dysfunction	24	23	2	0
Nystagmus	14	13	2	0
Pyramidal signs	39	38	3	0
Vomiting	10	10	0	0
Total	193	178	15	0

*Patients often have more than one clinical feature, so the number of patients is not 127. Only the major complaint or problem is listed.

MRI examination

MRI examination of the occipitocervical junction was performed in all patients. The depth of tonsillar herniation ranged from 3-14 mm, with an average depth of 9.37 mm. The cerebellar tonsil protruded through the foramen magnum by more than 5 mm in 98 patients and by 3-5 mm in 29 patients. SM was restricted to the cervical spinal cord in 21 patients, present in the cervical and thoracic spinal cord in 93 patients, and present in the whole spinal cord in 13 patients. The ratio of SM diameter to the spinal cord was less than 0.35 in 63 patients and greater than 0.35 in 46 patients. All patients exhibited obvious reductions or loss of the cisterna magna. A total of 33 patients had complications from basilar impressions, 27 had complications from occipitalization, 34 had complications from scoliosis, 10 had complications from Charcot's joints, and 12 had complications from hydrocephalus.

Surgical approaches

Under general anesthesia delivered by tracheal intubation, patients were rotated into

the prone position. Their heads were fixed and necks were bent slightly forward. Subsequently, a median incision was made from 1 cm below the external occipital protuberance to the C2 interspinalis, and the area from the squamous part of the occipital bone to the posterior edge of the foramen magnum was removed (Figure 1). This procedure made a bone window with a 3 x 4 cm area. The bone of the posterior edge of the foramen magnum was removed to a width of

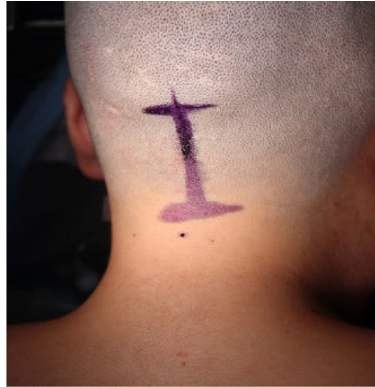

Figure 1. About 5cm surgical incision in the midline around the foramen magnum (from 1 cm below the external occipital protuberance to the C2 interspinalis).

2.5 cm and the posterior arch of the atlas was removed to a width of 2-2.5 cm. The thickened fascia surrounding the occipital was removed sharply under a microscope. After cutting the dura mater in a Y-pattern, the adhesions between the arachnoid, cerebral dura mater, cerebellar tonsil, and brain stem were separated under a microscope (Figure 2). The posterior pia mater of the cerebellar tonsil underwent electric coagulation and was removed to a level of 5-10

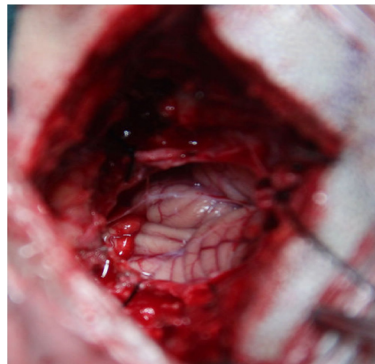


Figure 2. Intraoperative view after the dura is opened in “Y” format through median suboccipital craniotomy. The cerebellar tonsil is clearly visualized.

mm above the foramen magnum, thereby removing compression of the cerebellar tonsil to the medulla oblongata and cervical spinal cord. At the same time, compression of the lateral cerebellar tonsil to the nerve root was also removed. We explored the median aperture and two lateral apertures of the fourth ventricle and eliminated all adhesions, thereby removing the obstruction in the cerebrospinal fluid circulation of the fourth ventricle. The dura mater and arachnoid were simultaneously repaired using artificial dura mater, thereby markedly enlarg-

ing the subarachnoid space. The dura mater was hung at the edge of the bone window and the cisterna magna was formed by suturing the occipital muscles. External drainage tubes were placed outside the dura mater. Incisions were sutured tightly in layers. The patients were allowed to turn over only to axial positions and fixed with neck bands for 2-3 weeks.

Evaluation of therapeutic effects

Based on Tator scores (Tator et al., 1982), the therapeutic effects of the surgeries were categorized as valid or invalid. Any decline, improvement, or lack of an obvious change in the symptoms or signs of CM I-SM were considered valid. Exacerbation of the original symptoms or signs of the patients was considered invalid.

RESULTS

None of the 127 patients with CM I-SM died or showed disease deterioration. A total of 112 patients exhibited complete loss or improvement in their symptoms and 15 patients exhibited no change in their symptoms (Table 1). Two patients exhibited postoperative incision effusions, which were successfully treated by wound drainage and strengthening of dressings. Before discharge, 115 patients were re-examined by MRI and results showed that the cisterna magna was obviously larger after the surgeries in all patients. Reduced SM was observed in 76 patients. We performed telephone and outpatient follow-up in 84 patients. Amongst these patients, 79 exhibited improved symptoms, whereas five did not exhibit any changes. MRI re-examination in 44 patients showed that the cisterna magna was constructed successfully; eliminated or obviously reduced SM was noted in 42 patients (Table 2 and Figure 3).

Table 2. Postoperative symptoms/signs and change of syringomyelia in the follow-up of 84 patients.

Symptoms/Signs		Syringomyelia	
Improved	79	Eliminated/reduced	42
Unchanged	5	Unchange	2
Worse	0	Increased	0
Total	84	Total	44

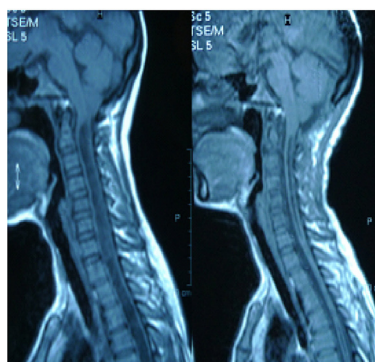


Figure 3. A. Preoperative MRI scan reveals tonsillar herniation extending below the foramen magnum in addition to obvious syringomyelia. B. Postoperative MRI scan reveals the absence of cerebellar tonsil with obvious remission of syringomyelia.

DISCUSSION

A significant amount of research has been done to determine the mechanisms underlying CMs since Chiari first reported and classified them in 1891. The view generally accepted of CM pathogenesis is that the hindbrain develops normally after birth but later herniates into the spinal canal due to overcrowding of the posterior cranial fossa and dysplasia of the occipital somites of the mesoderm at the embryonic stage or the developmental lag of occipital somites (Schijman, 2004; Park et al., 2009; Furtado et al., 2010). SM is secondarily derived from the abnormal anatomy of the foramen magnum. However, the pathogenesis of SM is still controversial. Three hypotheses have recently been proposed: a) Gardner's "water hammer effect" theory, b) Oldfield's "leakage" theory, and c) Williams's "the separation of intracranial pressure and pressure of the spinal canal" theory. However, no current theory can completely explain the pathogenesis of SM. Thus, the pathogenesis of CM-SM may involve multiple factors (Heiss et al., 1999; Furtado et al., 2009; Sekula et al., 2011).

Surgical management is the only effective method for the treatment of CM I-SM with definite symptoms. The indications for surgical treatment of CM I-SM include exhibiting signs and symptoms of nervous system impairments and rapid progression of the disease. The aim of surgical treatment is to enlarge the posterior cranial fossa volume, relieve compression of the cerebellar tonsil and liquid of SM to the brain stem and spinal cord, and improve the blood circulation of the cerebrospinal fluid and spinal cord, thereby allowing control of progressive nerve damage and promoting disease rehabilitation (Heiss et al., 1999; Schijman, 2004; Zhang et al., 2000, 2004; Huang et al., 2005; Attenello et al., 2008; Liu et al., 2008; Tariieo and Melo, 2008; Wu et al., 2010; Bao et al., 2011; Ma et al., 2012). Thus, regardless of the surgical approaches applied, the criteria for success should be an enlarged posterior cranial fossa volume, relief of compression of the hindbrain, construction of a smooth circulation channel of the cerebrospinal fluid, recovery of the physiological circulatory state of the cerebrospinal fluid, and elimination of compression and damage of SM to the spinal cord.

Commonly used surgical approaches for the treatment of CM I-SM include posterior fossa decompression, posterior fossa decompression with shunting for SM, and cerebellar tonsillectomies with duraplasty. Posterior fossa decompression enlarges the posterior cranial fossa volume, thereby providing some relief of the symptoms induced by compression of the foramen magnum. However, this approach does not address compression of the cerebellar tonsil to the medulla oblongata and the separated supply of the cerebrospinal fluid and abnormal cerebrospinal fluid circulation. Furthermore, this approach may induce drooping of the cerebellum and aggravate clinical symptoms (Zhang et al., 2004; Huang et al., 2005; Attenello et al., 2008; Liu et al., 2008). Given that shunting for SM does not recover normal cerebrospinal fluid circulation and may increase the risk of damage and infection in the spinal cord with unclear long-term effects, most scholars are not in favor of this treatment for CM I-SM (Zhang et al., 2000, 2004; Liu et al., 2008; Bao et al., 2011).

Cranio-cervical decompression with duraplasty and cerebellar tonsillectomy is a rational surgical approach that has exact clinical effects for the treatment of CM I-SM (Asgari et al., 2003; Huang et al., 2005; Liu et al., 2008; Bao et al., 2011; Ma et al., 2012;). Wu et al. (2010) emphasized that the aim of this surgical approach was to recover and enlarge the cisterna magna and restore normal cerebrospinal fluid circulation in the cisterna magna, thereby eliminating SM and providing symptom relief (Tariieo and Melo, 2008). In a follow-up study by Wu et al. (2010), SM was found to be obviously reduced in all patients examined and com-

pletely eliminated in eight patients. Liu et al. (2008) believed that tonsillar herniation should be removed to relieve its compression to the medulla oblongata and cervical spinal cord. For patients exhibiting symptoms from the nerve roots, they took special note to relieve compression of the lateral cerebellar tonsil to the nerve root of the accessory nerve and lower cranial nerves (Bao et al., 2011). Instead of osseous decompression, we considered removing the herniated cerebellar tonsil to improve the posterior fossa volume mismatch and communication between the fourth ventricle and the spinal compartment. No direct neurological deficit has been demonstrated as a result of tonsillar resection (Asgari et al., 2003; Zhang et al., 2004; Huang et al., 2005; Bao et al., 2011; Ma et al., 2012). However, the surgical effect of cerebellar tonsillectomy is controversial because tonsillar manipulation may later lead to further arachnoidal adhesions on the foramen magnum, with aggravation of syringomyelia and symptoms (Asgari et al., 2003). Our surgeries use a smaller incision to perform suboccipital decompression, cerebellar tonsillectomy, and duraplasty. As the cerebellar tonsil will retract after subpial resection and coagulation, the neurosurgeon can perform subpial cerebellar tonsillectomy as long as the upper pole of the cerebellar tonsil is exposed. Even if the cerebellar tonsil has reached the C2, a 5-cm incision is still adequate for the operation (Figure 1).

In this study, 127 patients with CM I-SM underwent craniocervical decompression with duraplasty and cerebellar tonsillectomy using microscopy. A total of 79 of 84 patients were found to exhibit improved symptoms during follow-up, demonstrating an effective rate of 94.1%. Re-examination by MRI in 44 patients showed successful construction of the cisterna magna, with eliminated or obviously reduced SM in 42 patients. Therefore, the surgical effects of craniocervical decompression with duraplasty and cerebellar tonsillectomy were much better than those reported for conventional posterior fossa decompression surgeries (Bao et al., 2011; Ma et al., 2012).

The main conclusions we have made regarding the surgeries based on our experiences are summarized as follows. First, bony decompression should expose the cerebellar tonsil. The edge of the foramen magnum must be removed to the 4 and 8 o'clock positions of the foramen magnum. The removal width of the arch of posterior atlas must not exceed 2.5 cm. These approaches should completely decompress and prevent postoperative craniocervical instability. Second, the cerebellar tonsil should be removed to 5-10 mm above the foramen magnum and direct vision of the median aperture of the fourth ventricle should be improved. Third, during removal of the cerebellar tonsil, the integrity of the pia mater of the cerebellar tonsil should be preserved to reduce postoperative adhesions. Fourth, clearing out the outflow tracts of the median aperture and two lateral apertures of the fourth ventricle is advisable to unobstruct cerebrospinal fluid circulation. Fifth, relieving the compression of the lateral cerebellar tonsil to the nerve root during the surgery should be performed carefully to allow for recovery of symptoms from the nerve root. Sixth, the dura mater and arachnoid should be sutured simultaneously to ensure effective construction of the cisterna magna. Seventh, artificial dura mater should be used to repair and suture the dura mater to reduce postoperative inflammatory reactions and adhesions.

Although the surgical results in most patients with CM I-SM were satisfactory, the symptoms of some patients did not improve after the surgeries, in particular symptoms relating to damage to the central canal of the spinal cord. These findings suggest that our surgical treatment can only prevent or retard disease progression and not reverse damage to the spinal cord. Thus, early diagnoses should be performed and surgeries should be done in patients with definite symptoms. In addition, we found cell apoptosis and necrosis in the herniation of the

cerebellar tonsil. Whether or not cell apoptosis exists in delayed cervical spinal lesions, and whether or not relationships exist between relieved symptoms after the surgery and cell regeneration must be explored in future research.

In summary, CM I-SM is a complex disease with variable clinical manifestations for which surgical management is an effective therapeutic method. Although surgical approaches are not yet uniformly successful in the treatment of CM I-SM, craniocervical decompression with duraplasty and cerebellar tonsillectomy is a rational surgical approach that may produce clinical effects recognized by most scholars. In the future, clinicians must be able to diagnose CM I-SM and use treatments that are more appropriate.

REFERENCES

- Arnold J (1994). Myelocyst transportation Von Gewebskeimen und Symptodie. *Beitr. Path. Anat. Allgem. Path.* 37: 1-28.
- Asgari S, Engelhorn T, Bschor M, Sandalcioglu IE, et al. (2003). Surgical prognosis in hindbrain related syringomyelia. *Acta Neurol Scand.* 107: 12-21.
- Attenello FJ, McGirt MJ, Gathinji M, Dato G, et al. (2008). Outcome of Chiari-associated syringomyelia after hindbrain decompression in children: analysis of 49 consecutive cases. *Neurosurgery.* 62: 1307-1313.
- Bao CS, Yang FB, Liu L, Wang B, et al. (2011). Cerebellar tonsillectomy and reconstruction of the cistern magna for treatment of syringomyelia with Chiari malformation. *Chin. J. Neuromed.* 10: 993-995.
- Chiari H (1891). Über Veränderungen des Kleinhirns infolge von Hydrocephalie des Grosshirns. *Dtsch med. Wschr.* 17: 1172-1175.
- Chiari H (1895). Über Veränderungen des Kleinhirns, des Pons und der Medulla Oblongata in Folge von congenitaler Hydrocephalie des Grosshirns. *Dtsch Akd Wissensch.* 63: 71-125.
- Finlayson AI (1981). Syringomyelia and related conditions. In: Baker AB, Baker LH (Eds). *Clinical Neurology*, Philadelphia. 1-17.
- Furtado SV, Reddy K and Hegde AS (2009). Posterior fossa morphometry in symptomatic pediatric and adult Chiari I malformation. *J. Clin. Neurosci.* 16: 1449-1454.
- Furtado SV, Thakar S, Venkatesh PK, Reddy K, et al. (2010). Morphometric analysis of foramen magnum dimensions and intracranial volume in pediatric Chiari I malformation. *Acta Neurochir.* 152: 221-227.
- Heiss JD, Patronas N, DeVroom HL, Shawker T, et al. (1999). Elucidating the pathophysiology of syringomyelia. *J. Neurosurg.* 91: 553-562.
- Huang SQ, Xiao QH, Li GP, Cheng YZ, et al. (2005). Microsurgical treatments of Chiari I malformation associated with syringomyelia: analysis of 310 cases. *Chin. J. Neurosurg.* 21: 100-102.
- Liu H, Zheng L and Chang SF (2008). Microsurgical treatment of syringomyelia associated with Arnold-Chiari malformation. *J. Pract Med.* 24: 3209-3210.
- Ma JP, You C, Chen HF, Huang S, et al. (2012). Cerebellar tonsillectomy with suboccipital decompression and duraplasty by small incision for Chiari I malformation (with syringomyelia): long term follow-up of 76 surgically treated cases. *Turk Neurosurg.* 22: 274-279.
- Park YS, Kim DS, Shim KW, Kim JH, et al. (2009). Factors contributing improvement of syringomyelia and surgical outcome in type I Chiari malformation. *Childs Nerv. Syst.* 25: 453-459.
- Schijman E (2004). History, anatomic forms, and pathogenesis of Chiari I malformations. *Childs Nerv. Syst.* 20: 323-328.
- Schwalbe E and Gredig M (1907). Über Entwicklungsstörungen des Kleinhirns, Hirnstammes und bei Spina bifida (Arnold'sche Missbildung). *Beitr. Path. Anat. Path.* 71-85.
- Sekula RF Jr, Arnone GD, Crocker C, Aziz KM, et al. (2011). The pathogenesis of Chiari I malformation and syringomyelia. *Neurol. Res.* 33: 232-239.
- Simon TH (1875). Beiträge zur Pathologie und pathologischen Anatomie des Central-Nervensystem. *Arch. Psychiat Nervenkr.* 5: 108-163.
- Tariego MA and Melo LR (2008). Retrospective study of patients with Chiari malformation submitted to surgical treatment. *Arq. Neuropsiquiatr.* 66: 184-188.
- Tator CH, Meguro K and Rowed DW (1982). Favorable results with syringosubarachnoid shunts for treatment of syringomyelia. *J. Neurosurg.* 56: 517-523.
- Williams H (2008). A unifying hypothesis for hydrocephalus, Chiari malformation, syringomyelia, anencephaly and spina bifida. *Cerebrospinal Fluid Res.* 5: 7.

- Wu HB, Chen J and Li AM (2010). Reconstruction of the cistern magna for treatment of syringomyelia with Chiari I malformation. *Chin. J. Pract Nerv. Dis.* 13: 89-90.
- Zhang YQ, Wang ZC, Ma ZY and Li ZH (2004). Chiari malformation with syringomyelia: surgical treatment with tonsillectomy plus central canal opening. *Chin. J. Neurosurg.* 20: 215-217.
- Zhang YZ, Zhou DB, Qiao GY and Sun ZH (2000). Reconstruction of the cistern magna to treat the syringomyelia associate Chiari type I malformation. *Chin. J. Neurosurg.* 16: 274-276.