



A novel stop codon mutation in exon 1 (558C>A) of the *UGT1A1* gene in a Thai neonate with Crigler-Najjar syndrome type I

N. Wanlapakorn¹, P. Nilyanimit¹, T. Vorawandthanachai¹, T. Deesudjit²,
N. Dumrongpisutikul³ and Y. Poovorawan¹

¹Center of Excellence in Clinical Virology, Department of Pediatrics,
Faculty of Medicine, Chulalongkorn University, Bangkok, Thailand

²Division of Neurology, Department of Pediatrics, Faculty of Medicine,
Chulalongkorn University, Bangkok, Thailand

³Department of Radiology, Faculty of Medicine, Chulalongkorn University,
Bangkok, Thailand

Corresponding author: Y. Poovorawan
E-mail: Yong.P@chula.ac.th

Genet. Mol. Res. 14 (1): 419-425 (2015)

Received January 14, 2014

Accepted March 28, 2014

Published January 23, 2015

DOI <http://dx.doi.org/10.4238/2015.January.23.15>

ABSTRACT. Human uridine 5'-diphosphate-glucuronosyltransferases play a critical role in detoxification by conjugating bilirubin with glucuronic acid. Impaired or reduced enzymatic activity causes a spectrum of clinical disorders such as Crigler-Najjar syndrome type I (CN1), Crigler-Najjar syndrome type II, and Gilbert's syndrome. CN1 is a severe form of unconjugated hyperbilirubinemia caused by homozygous or compound heterozygous mutations in the gene for uridine 5'-diphosphate glucuronosyltransferase 1 family, polypeptide A1 (*UGT1A1*), resulting in complete loss of enzyme function. Here, we report a novel homozygous mutation of *UGT1A1* in a female Thai infant who was diagnosed with CN1, and her parents were found to be heterozygous carriers. The patient was homozygous for the c.558C>A mutation, which resulted in a premature stop codon in exon

1. Her asymptomatic parents were carriers of the nonsense c.558C>A mutation. Our result suggests an important role for homozygous c.558C>A mutations in the *UGT1A1* gene in the development of severe unconjugated hyperbilirubinemia.

Key words: Crigler-Najjar syndrome; Kernicterus; Mutations; *UGT1A1*

INTRODUCTION

Crigler-Najjar syndrome is a very rare disease associated with impaired uridine 5'-diphosphate (UDP)-glucuronosyltransferase activity (Maruo et al., 2003). This enzyme is responsible for bilirubin glucuronidation, in which glucuronic acid is conjugated to bilirubin to enhance its solubility in water for excretion to the biliary system (Sugatani, 2013). Conjugation is necessary for the excretion of bilirubin into bile. The complete or partial loss of enzyme function results in the accumulation of unconjugated bilirubin.

The *UGT1A1* gene, located at the 2q37 locus on chromosome 2, has five exons and encodes an enzyme that is critical for bilirubin conjugation (Sugatani, 2013). Mutations in the *UGT1A1* gene result in reduced or absent enzyme function, which can cause a group of diseases known as Crigler-Najjar syndrome and Gilbert's syndrome. Patients with Crigler-Najjar syndrome type I (CN1) show no enzyme function, while those with Crigler-Najjar syndrome type II (CN2) have less than 30% of normal enzyme function (Strassburg, 2010). Thus, the signs and symptoms of CN1 are more severe than those of CN2, while only mild hyperbilirubinemia is detected in patients with Gilbert syndrome. Some affected individuals with a high level of unconjugated bilirubin develop a form of brain damage known as kernicterus, which results in cognitive, perceptual, motor, and auditory disorders (Shapiro, 2003).

To date, approximately 130 mutations in the *UGT1A1* gene causing Crigler-Najjar syndrome and Gilbert's syndrome have been identified (Canu et al., 2013), most of which are single-nucleotide substitutions (70%). Expression of the *UGT1A1* gene is controlled by the TATAA box in the promoter region. The wild-type promoter contains 6 repeated thymine and adenine (TA) sequences or [A(TA)₆TAA] (6/6). Previous studies have demonstrated that increased repetitions of the TA motif lead to decreased efficiency of gene expression (Kaplan et al., 2001), resulting in clinical manifestation of Gilbert's syndrome.

Here, we report the case of a 1-year-old girl with CN1 caused by a novel nonsense mutation at nucleotide position 558 from C to A, changing a cysteine to a stop codon. The promoter regions of the *UGT1A1* gene in this patient and in her family members were wild-type (6/6).

MATERIAL AND METHODS

The study was approved by the Institutional Review Board, Faculty of Medicine, Chulalongkorn University, Thailand. Written informed consent was obtained from the patient's parents.

Patient

A 1-month-old Thai female infant presented with jaundice observed by her parents beginning at the age of 2 weeks. She was born at 38 weeks of gestation by cesarean sec-

tion because of an unfavorable cervix and had a birth weight of 3520 grams. She was the first child of the family by consanguineous marriage, as her grandparents were 2nd cousins. There were no postnatal complications and she was discharged at the age of 4 days.

Her mother returned to the community hospital in the Nakon Ratchaseema Province because of visible jaundice when the child was 1 month old. Clinical examination was normal. Initial investigation revealed an increase in total serum bilirubin of 18.1 mg/dL, direct bilirubin of 1.5 mg/dL, aspartate aminotransferase of 41 U/L, alanine aminotransferase of 14 U/L, alkaline phosphatase of 455 U/L, and both the baby and mother's blood group was B and both were Rh positive. Her thyroid function test was normal and peripheral blood smear showed no evidence of hemolysis. She was treated with single phototherapy; however, the next day, her total serum bilirubin levels continued to increase to 30.4 mg/dL and she developed retrocollis and upward gaze palsy. She was diagnosed with acute bilirubin encephalopathy and total exchange transfusion was commenced. Total serum bilirubin was successfully reduced to 19.2 mg/dL; however, although single phototherapy was administered daily for 1 month, total serum bilirubin still remained at 12-20 mg/dL. The patient was discharged with home phototherapy prior to her referral to the King Chulalongkorn Memorial Hospital.

Upon arrival at King Chulalongkorn Memorial Hospital, the patient was 6 months old and showed global delayed development. She could not lift her head for a sustained period or place her hands together in midline. Upon physical examination, hypertonia of the extremities and impaired upward gaze were noted. Her total serum bilirubin level was still high (16.4 mg/dL) despite daily phototherapy. Her mother's serum bilirubin level was normal, whereas her father's was slightly elevated to 1.8 mg/dL (normal range, 0.1-1.2 mg/dL) (Arora et al., 2009). No significant increase in liver enzymes was recorded in either parent (Table 1).

Table 1. Liver function tests of the patient obtained at 6 months of age and of her parents at King Chulalongkorn Memorial Hospital.

Liver function test	Patient	Father	Mother
Albumin (g/dL)	4.1	5.0	4.5
Total bilirubin (g/dL)	16.4	1.8	0.6
Direct bilirubin (g/dL)	0.89	0.54	0.2
AST (U/L)	49	23	17
ALT (U/L)	35	47	10
ALP (U/L)	150	59	81

AST = aspartate aminotransferase; ALT = alanine aminotransferase; ALP = alkaline phosphatase.

The patient had been treated with phenobarbital at a dosage of 5 mg·kg⁻¹·day⁻¹ for 4 months; however, there was no significant decrease in total serum bilirubin level after treatment. Phenobarbital, an enzyme inducer in bilirubin conjugation, has been shown to be a useful approach for reducing total serum bilirubin by more than 25% in CN2 patients, while it provides no benefits for CN1 patients (Kimura et al., 1991; Jansen, 1999). Based on the presentation of severe unconjugated hyperbilirubinemia and persistently high bilirubin levels after phenobarbital treatment, the diagnosis of CN1 was made. Brain magnetic resonance imaging (MRI) and electroencephalogram were performed at the age of 1 year. Brain MRI in the axial T1WI image showed symmetrical isointensity in bilateral globi pallidi, whereas in the axial FLAIR image, symmetrical hyperintensity in bilateral globi pallidi was observed (Figure

1A and B). These features are distinct characteristics of bilirubin encephalopathy (Katar et al., 2008). Routine electroencephalogram revealed a normal result. Currently, the patient is 1 year of age but has a developmental age equal to a 3-month-old baby. She can lift her head for a short period but cannot roll over. Peripheral hypertonia improved after baclofen treatment; however, athetoid movements of both hands and positive tonic neck reflex were noted. A hearing screening test using MADSEN AccuScreen® (Otometrics, Taastrup, Denmark) revealed normal results in both ears. Phenobarbital was discontinued because of its lack of efficacy in CN1 patients. Blood samples of the patient and her family were collected and subjected to molecular genetic analysis.

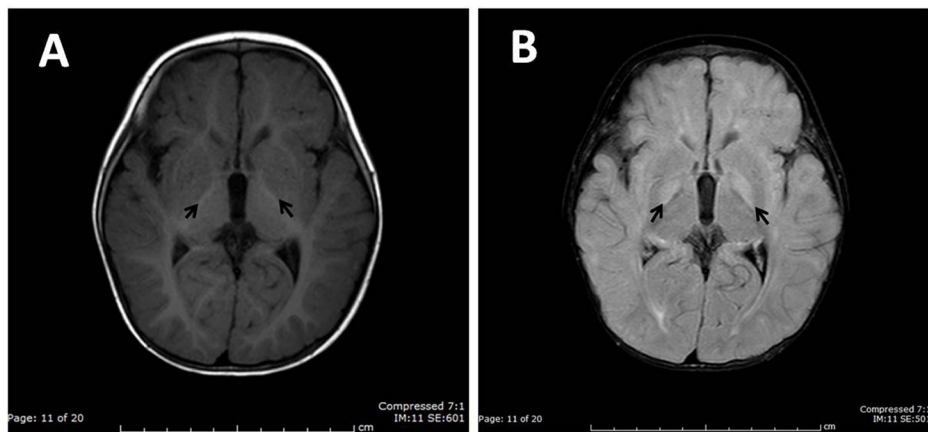


Figure 1. Brain MRI of a 1-year-old patient with history of bilirubin encephalopathy. Axial T1WI shows symmetrical isointensity in bilateral globi pallidi (A). Axial FLAIR image shows symmetrical hyperintensity in bilateral globi pallidi (B).

Methods

One microliter anti-coagulated (ethylenediamine tetraacetic acid-treated) blood samples was collected from the infant and her parents. Peripheral blood mononuclear cells were separated using lymphocyte separation medium (Wisent Inc., Quebec, Canada). Genomic DNA was extracted from 100 μ L leukocytes using phenol-chloroform-isoamyl alcohol extraction and ethanol precipitation (Nilyanimit et al., 2013). The DNA pellet was stored at -20°C until analysis.

For mutation screening, the promoter and 5 exons of *UGT1A1* were amplified by polymerase chain reaction using the primer sets described in a previous study (Nilyanimit et al., 2013). Amplified products were isolated by 2% agarose gel electrophoresis and purified using the PCRExtract and GelExtract Mini Kit (5 PRIME Inc., Hilden, Germany). Direct sequencing was performed by First-BASE Laboratories Sdn Bhd (Selangor, Darul Ehsan, Malaysia).

Nucleotide sequences obtained by direct sequencing were edited and assembled using SEQMAN (LASERGENE program package; DNASTAR, Inc., Madison, WI, USA) and subsequently subjected to Basic Local Alignment Search Tool analysis. The *UGT1A1* accession No. NC_000002.11 from GenBank was used as the reference sequence, for which the “A” of the ATG translation initiation site represents nucleotide +1.

RESULTS

Mutation screening of the infant indicated that the promoter had a normal wild-type TATA box sequence [A(TA)₆TAA]. Analysis of intra-exon mutations in *UGT1A1* showed a homozygous C to A transversion (C>A) at nucleotide position 558 in exon 1 (c.558C>A). This nucleotide change was predicted to cause a nonsense mutation (p.C186X). Both parents of the patient showed the normal wild-type promoter [A(TA)₆TAA] and heterozygous nucleotide changes from C to A at position 558, explaining the homozygous c.558C>A mutation in the patient (Figure 2). No mutations were detected in any other exons.

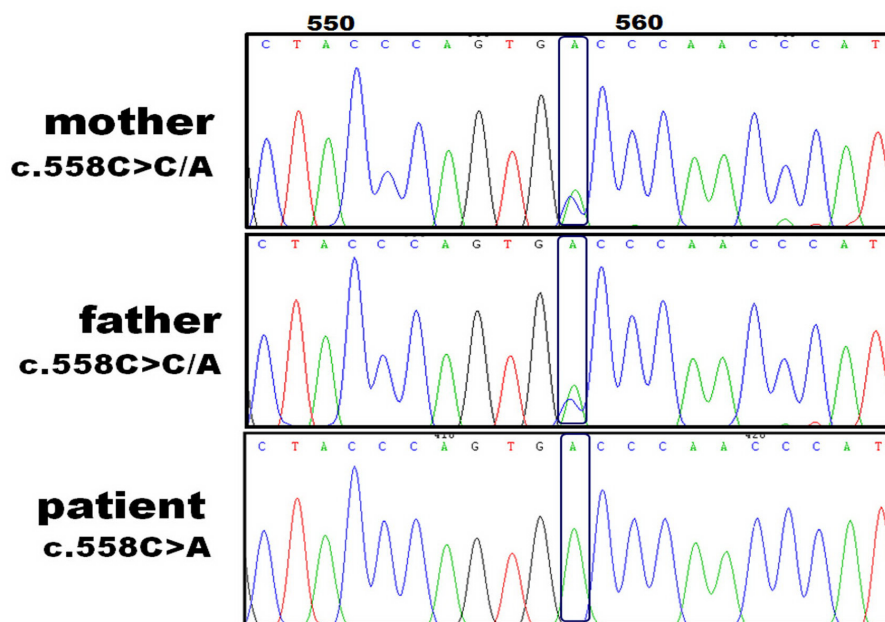


Figure 2. DNA sequence analysis of the patient and her parents. Nucleotide sequence showed heterozygous c.558C>A mutations in parents and homozygous c.558C>A mutations in the patient.

DISCUSSION

The novel homozygous nonsense mutation c.558C>A in the *UGT1A1* gene identified in our study was responsible for the premature stop codon on exon 1, resulting in a non-functioning UDP-glucuronosyltransferase enzyme. To date, more than 50 mutations causing CN1 have been described, most of which (65.4%) are missense/nonsense mutations. Nonsense mutations were found to be more related to CN1 compared to other forms of unconjugated hyperbilirubinemia, as the premature stop codon results in severely truncated non-functioning enzymes (Stenson et al., 2009).

The asymptomatic parents of the infant were heterozygous for c.558C>A, and both showed the normal wild-type promoter [A(TA)₆TAA]. Her mother's liver function test was normal, whereas her father's total serum bilirubin was slightly elevated. The exact cause of

mild hyperbilirubinemia in the father remains unknown. Differential diagnoses included hemolysis, hepatic dysfunctions, and Gilbert's syndrome. Previous studies have found that heterozygous mutations in the *UGT1A1* gene can result in different phenotypes. Some types of heterozygous mutations, such as R341X, have been observed in silent carriers, whereas other types, such as Q331X and C280X, may result in CN2 or Gilbert's syndrome.

In conclusion, we reported a case of CN1 in a Thai neonate presenting with visible jaundice. She experienced severe unconjugated hyperbilirubinemia with acute kernicterus, and brain MRI was consistent with bilirubin encephalopathy. Molecular diagnosis confirmed a homozygous c.558C>A mutation, which resulted in a premature stop codon in exon 1 of the *UGT1A1* gene. Our results suggest an important role for the homozygous c.558C>A mutation in the development of CN1.

Conflicts of interest

The authors declare no conflict of interest.

ACKNOWLEDGMENTS

We would like to thank Dr. Soranont Trytilanunt for reviewing the clinical data at Nakon Ratchaseema Hospital. Research supported by the Higher Education Research Promotion and National Research University Project of Thailand, Office of the Higher Education Commission (#HR1155A-55), the Thailand Research Fund (#DPG5480002), the Center of Excellence in Clinical Virology, Chulalongkorn University, Integrated Innovation Academic Center, IIAC, Chulalongkorn University Centenary Academic Development Project (#CU56-HR01), the Ratchadaphiseksomphot Endowment Fund of Chulalongkorn University (#RES560530093), and Research Chair Grant, NSTDA and King Chulalongkorn Memorial Hospital Thai Red Cross Society, MK Restaurant Company Limited and The Siam Cement Pcl. for their generous support. We would like to thank Ms. Petra for reviewing this manuscript.

REFERENCES

- Arora V, Kulkarni RK, Cherian S, Pillai R, et al. (2009). Hyperbilirubinemia in normal healthy donors. *Asian J. Transfus. Sci.* 3: 70-72.
- Canu G, Minucci A, Zuppi C and Capoluongo E (2013). Gilbert and Crigler Najjar syndromes: an update of the UDP-glucuronosyltransferase 1A1 (*UGT1A1*) gene mutation database. *Blood Cells Mol. Dis.* 50: 273-280.
- Jansen PL (1999). Diagnosis and management of Crigler-Najjar syndrome. *Eur. J. Pediatr.* 15: S89-S94.
- Kaplan M, Hammerman C and Beutler E (2001). Heterozygosity for a polymorphism in the promoter region of the *UGT1A1* gene. *J. Hepatol.* 35: 148-150.
- Katar S, Akay HO, Taskesen M and Devecioglu C (2008). Clinical and cranial magnetic resonance imaging (MRI) findings of 21 patients with serious hyperbilirubinemia. *J. Child Neurol.* 23: 415-417.
- Kimura A, Ushijima K, Kage M, Mahara R, et al. (1991). Neonatal Dubin-Johnson syndrome with severe cholestasis: effective phenobarbital therapy. *Acta Paediatr. Scand.* 80: 381-385.
- Maruo Y, Poon KK, Ito M, Iwai M, et al. (2003). Co-occurrence of three different mutations in the bilirubin UDP-glucuronosyltransferase gene in a Chinese family with Crigler-Najjar syndrome type I and Gilbert's syndrome. *Clin. Genet.* 64: 420-423.
- Nilyanimit P, Krasaelap A, Foonoi M, Chongsrisawat V, et al. (2013). Role of homozygous A(TA)₇TAA promoter polymorphism and an exon 1 heterozygous frameshift mutation *UGT1A1* in Crigler-Najjar syndrome type II in a Thai neonate. *Genet. Mol. Res.* 12: 3391-3397.
- Shapiro SM (2003). Bilirubin toxicity in the developing nervous system. *Pediatr. Neurol.* 29: 410-421.

- Stenson PD, Mort M, Ball EV, Howells K, et al. (2009). The Human Gene Mutation Database: 2008 Update. *Genome Med.* 1: 13.
- Strassburg CP (2010). Hyperbilirubinemia syndromes (Gilbert-Meulengracht, Crigler-Najjar, Dubin-Johnson, and Rotor syndrome). *Best Pract. Res. Clin. Gastroenterol.* 24: 555-571.
- Sugatani J (2013). Function, genetic polymorphism, and transcriptional regulation of human UDP-glucuronosyltransferase (UGT) 1A1. *Drug Metab. Pharmacokinet.* 28: 83-92.