



Case Report

Familial primary open-angle glaucoma: a case report

K. Shi, L. Zhao and C.Y. Wang

Department of Ophthalmology,
The Second Affiliated Hospital of Nanchang University,
Nanchang, Jiangxi Province, China

Corresponding author: K. Shi
E-mail: 86325294@qq.com

Genet. Mol. Res. 13 (2): 3162-3164 (2014)
Received February 17, 2014
Accepted April 8, 2014
Published April 17, 2014
DOI <http://dx.doi.org/10.4238/2014.April.17.12>

ABSTRACT. Primary open-angle glaucoma (POAG) is a disease that is often inherited, but the rules governing its inheritance are inconclusive. Herein, we report a case of POAG in a Chinese family. A 25-year-old female patient was referred to our department with progressive visual acuity decline in her left eye for the past 3 years. Ophthalmological examination supported our diagnosis of POAG in both eyes. We recorded the case history and clinical data of the proband and her family members and followed standard genetic study procedures. In this family, there were 8 individuals (4 male and 4 female) diagnosed with POAG, 2 of whom died. Genetic analysis revealed that the inheritance pattern of POAG in this family is autosomal dominant.

Key words: Primary open-angle glaucoma; Genetics;
Autosomal dominant

INTRODUCTION

Glaucoma is the leading cause of irreversible blindness, of which primary open-angle glaucoma (POAG) is the major type (Kokotas et al., 2012). POAG tends to be hereditary, but the mechanisms underlying the inheritance of this condition have yet to be elucidated. Herein, we identified familial POAG affecting 8 patients and analyzed the inheritance pattern.

CASE REPORT

A 25-year-old female patient was referred to our department with progressive visual acuity decline in the left eye for the past 3 years. Ophthalmological examination revealed right eye visual acuity of 20/20 and left eye visual acuity of 20/70. There were no apparent pathological changes in the anterior segment of either eye. Gonioscopy examination showed normal appearance and open anterior chamber angle without peripheral anterior synechiae. Fundus examination showed an acquired optic nerve pit in both eyes. Cup/disk (C/D) asymmetry was 0.5 and 0.7 in the right and left eyes, respectively. Intraocular pressure (IOP) in the right eye was 26.5 mmHg and in the left eye it was 38.1 mmHg. Visual field in the right eye showed nasal paracentral scotoma, while the left eye demonstrated left nasal step. The diagnosis was POAG in both eyes and the patient subsequently underwent trabeculectomy.

After obtaining ethics committee approval from the Second Affiliated Hospital of Nanchang University and signed informed consent from the patient’s family members, we conducted glaucoma examinations and genetic investigations following the tenets of the Declaration of Helsinki. The survey revealed that there are 4 generations of 22 people (14 male and 8 female) in this family. Eight POAG patients were identified, including the proband and her grandmother, father, aunt, eldest brother, second elder brother, cousin, and niece (Figure 1). The age at diagnosis (alive) was between 13 and 35 years (26.3 ± 2.8 years), which is considered juvenile POAG. Collectively, their visual field impairments were mostly early or metaphase-related, and the IOP ranged from 25.81 to 38.80 mmHg (32.51 ± 4.45 mmHg). Their prognoses were satisfactory after undergoing an operation or receiving medication.

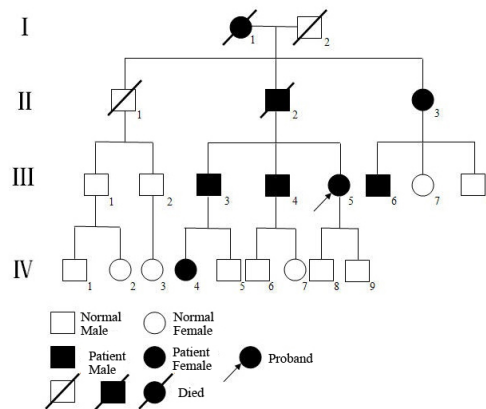


Figure 1. Pedigree of PAOG inheritance.

DISCUSSION

Since patient 4 on line III of Figure 1 is a rural doctor, all patients in the proband's family accepted timely treatment with high compliance. Follow-up visual field examinations showed no apparent deterioration or only darkening of the scotoma and no obvious scotoma extension. The family members' IOPs were within the normal range. This familial POAG has the following genetic characteristics: 1) POAG patients were found in each generation without atavism; 2) the incidence of POAG is equal between male and female patients (4 vs 4); 3) if parents were not patients, neither were their children; and 4) the family had normal marriages without inbreeding. On the basis of the above information, we concluded that the genetic inheritance pattern in this familial POAG is autosomal dominant.

Owing to pathologically elevated IOP, POAG manifests as an acquired optic nerve pit and visual field defect with open anterior chamber angle. Previous studies found that 13-47% of POAG patients have a positive family history (Gemenetzi et al., 2012; Mabuchi et al., 2012); nevertheless, there is no consensus regarding the method by which POAG is inherited. It has been acknowledged that the inheritance pattern can be autosomal dominant, autosomal recessive, and multifactorial (Allingham et al., 2009). Typical POAG is not difficult to diagnose; however, since POAG onset is insidious and progresses slowly, most patients present to the clinic with irreversible optic nerve damage. Hence, early POAG diagnosis is one of the most challenging aspects of current ophthalmological clinical work.

Genetic analysis technology was heralded as a solution to the POAG genetic conundrum. Scientists have identified *MYOC*, *OPTN*, *WDR36*, and *CYP11B1* as being related to POAG, and found that mutations in these genes play a key role in POAG onset. Although familial patients are the best research subjects for inherited diseases, genes involved in POAG pathogenesis show regional and ethnic differences. For example, there are over 70 specific mutations in the *MYOC* gene, but none of them are shared between three races (Mongoloid, Caucasoid, and Negroid) (Gong et al., 2004). Therefore, identification of specific mutations of genes involved in POAG pathogenesis in Chinese patients supplements current POAG genetic research and is the focus of our future study.

REFERENCES

- Allingham RR, Liu Y and Rhee DJ (2009). The genetics of primary open-angle glaucoma: a review. *Exp. Eye Res.* 88: 837-844.
- Gemenetzi M, Yang Y and Lotery AJ (2012). Current concepts on primary open-angle glaucoma genetics: a contribution to disease pathophysiology and future treatment. *Eye (Lond)* 26: 355-369.
- Gong G, Kosoko-Lasaki O, Haynatzki GR and Wilson MR (2004). Genetic dissection of myocilin glaucoma. *Hum. Mol. Genet.* 13 Spec. No 1: R91-102.
- Kokotas H, Kroupis C, Chiras D, Grigoriadou M, et al. (2012). Biomarkers in primary open angle glaucoma. *Clin. Chem. Lab. Med.* 50: 2107-2119.
- Mabuchi F, Sakurada Y, Kashiwagi K, Yamagata Z, et al. (2012). Association between genetic variants associated with vertical cup-to-disc ratio and phenotypic features of primary open-angle glaucoma. *Ophthalmology* 119: 1819-1825.