GMR
The Original

IMMUNOHISTOCHEMICAL EVALUATION OF BCL-2 AND GLYPICAN-3 EXPRESSION IN NORMAL ORAL MUCOSA AND DIFFERENT HISTOLOGICAL GRADES OF ORAL SQUAMOUS CELL CARCINOMA: A RETROSPECTIVE COMPARATIVE STUDY

Naresh Gehlot[1], Kunzang Dolma[2], Suheel H. Latoo[3], Mohd. Shafi Dar[4], Nitish Bhat[5], Tariq Ahmad Lone[6]

[1]Postgraduate Scholar, Department of Oral & Maxillofacial Pathology & Microbiology, Government Dental College & Hospital, Srinagar, India.
[2]Postgraduate Scholar, Department of Oral & Maxillofacial Pathology & Microbiology, Government Dental College & Hospital, Srinagar, India.
[3]Professor & Head, Department of Oral & Maxillofacial Pathology & Microbiology, Government Dental College & Hospital, Srinagar, India.
[4]Associate Professor, Department of Oral & Maxillofacial Pathology & Microbiology, Government Dental College & Hospital, Srinagar, India.
[5]Assistant Professor, Department of Oral & Maxillofacial Pathology & Microbiology, Government Dental College & Hospital, Srinagar, India.
[6]Senior Resident, Department of Oral & Maxillofacial Pathology & Microbiology, Government Dental College & Hospital, Srinagar, India.
***Corresponding author**: Dr Naresh Gehlot, Email ID : Nghelot@gmail.com

ABSTRACT

Background: Oral squamous cell carcinoma (OSCC) is the predominant malignancy of the oral cavity. Dysregulation of apoptosis and growth-factor signalling contributes to oral carcinogenesis. B-cell lymphoma 2 (Bcl-2), an anti-apoptotic protein, and glypican-3 (GPC3), a cell-surface heparan-sulphate proteoglycan, have been investigated as immunohistochemical markers in OSCC.

Aim: To compare Bcl-2 and GPC3 immunoexpression in normal oral mucosa and well, moderately and poorly differentiated OSCC.

Methods: This retrospective comparative study included 36 formalin-fixed, paraffin-embedded tissue specimens: normal oral mucosa (n=9), well-differentiated OSCC (WDSCC; n=9), moderately differentiated OSCC (MDSCC; n=9) and poorly differentiated OSCC (PDSCC; n=9). H&E sections were reviewed for diagnosis and grading. Bcl-2 and GPC3 immunostaining was assessed by two observers in five randomly selected high-power fields (×400), considering cellular localization, staining pattern, percentage of positive cells and intensity. The immunoreactive score (IRS) was calculated as percentage score (0–4) multiplied by intensity score (0–3). .

Results: Bcl-2 IRS categories differed across the four study groups (Monte Carlo Fisher–Freeman–Halton test, $p<0.00001$). GPC3 IRS categories also differed across groups ($p<0.00001$). GPC3 was IRS-negative in all normal mucosal controls, while 66.7% of PDSCC cases showed strongly positive IRS. These are unadjusted group comparisons based on the available aggregate frequency tables.

Conclusion: In this series, both markers showed a descriptive shift towards higher IRS categories with increasing OSCC grade, and GPC3 was negative in all normal mucosal controls. These findings support further evaluation of Bcl-2 and GPC3 as adjunctive tissue markers. The cross-sectional design and absence of outcome data do not establish independent prognostic value.

KEYWORDS: Oral squamous cell carcinoma; Bcl-2; glypican-3; immunohistochemistry; immunoreactive score; histological grade.

INTRODUCTION

Oral squamous cell carcinoma (OSCC) is the most common malignant epithelial neoplasm of the oral cavity and represents the major histological type of oral cancer. Its development is a multistep process in which genetic and epigenetic alterations disrupt epithelial proliferation, differentiation, cell-cycle regulation, apoptosis and interactions with the tumour microenvironment. Histopathological grading remains an important component of diagnosis; however, tumour differentiation alone does not capture the full molecular heterogeneity of OSCC. Immunohistochemical assessment of proteins involved in cell survival and growth signalling may therefore provide complementary information about the biological changes accompanying oral carcinogenesis [1,2].

Bcl-2 family consists of both pro- and anti-apoptotic members. Bcl-2 and Bcl-XL are anti-apoptotic proteins, while Bax and Bak are pro-apoptotic proteins.[3] The actual outcome of a cell challenged by an apoptotic

stimulus is determined by the relative concentration of pro and anti-apoptotic members.[4] The Bcl-2 proto-oncogene product, which is encoded on chromosome 18q21, is a 26-kDa protein that is a component of the nuclear envelope, endoplasmic reticulum and outer mitochondrial membrane.[5]
Bcl-2 is an anti-apoptotic protein that is controlled by p53 and interacts with it. It is a component of the regulatory system that controls the cell cycle and apoptosis induction.[6] It inhibits cell apoptosis by preventing the release of cytochrome C from the mitochondrion to the cytoplasm[7]. Overexpression of Bcl-2 alters planned cell death, resulting in the persistence of cells that do not die. Bcl-2 is expressed in stem cell zones such as the basal layers in the normal proliferative epithelium, where it prevents the death of cells in the regenerative compartment. Overexpression of the Bcl-2 protein has been discovered in the early stages of epithelial carcinogenesis.[8,9]

Glypican-3 (GPC3) is a glycosylphosphatidylinositol-anchored cell-surface heparan-sulphate proteoglycan belonging to the glypican family (GPC1–GPC6) [10]. It is encoded by the GPC3 gene on chromosome Xq26 and is expressed during embryonic development, while expression is limited in many adult tissues. GPC3 can modulate signalling pathways involved in growth and morphogenesis, including Wnt/β-catenin, Hedgehog, fibroblast growth factor and bone morphogenetic protein pathways [10,11]. In oral squamous cell carcinoma (OSCC), numerous studies have demonstrated that GPC3 expression is upregulated in malignant epithelium compared to normal oral mucosa. Immunohistochemically, tumor cells show cytoplasmic and membranous positivity for GPC3, which correlates significantly with poor histological differentiation, advanced tumor stage, lymph node metastasis, and reduced overall survival [12,13].
The purpose of the present study is to evaluate and correlate the expression of Bcl-2 & Glypican-3 in progression of OSCC and to compare the expression of Bcl-2 & Glypican-3 in different grades of OSCC.

MATERIALS AND METHODS

Study design and study material

The study was conducted in the Postgraduate Department of Oral and Maxillofacial Pathology, Government Dental College and Hospital, Srinagar, after approval by the Institutional Ethics Committee. This retrospective comparative immunohistochemical study comprised 36 archival formalin-fixed, paraffin-embedded tissue specimens. The study groups were normal oral mucosa (NOM; n=9), WDSCC (n=9), MDSCC (n=9) and PDSCC (n=9). Histopathological diagnosis and grading were confirmed on H&E-stained sections.

Eligibility criteria

The study included histopathologically diagnosed and graded OSCC specimens and normal oral mucosal specimens. Exclusion criteria for OSCC included previously treated cases and specimens with associated pathology. Normal mucosal controls from individuals with areca-nut or tobacco habits, epithelial alterations or inflammatory infiltrates were excluded.

Histopathological assessment

For each case, consecutive tissue sections of approximately 3–4 μm were prepared. H&E-stained sections were examined by two observers to confirm the diagnosis and histological grade. The final groups comprised nine cases each of WDSCC, MDSCC and PDSCC, with nine normal oral mucosal controls.

Immunohistochemistry

Two sections, each 4 μm thick, were obtained from formalin-fixed, paraffin-embedded tissue blocks and mounted on positively charged slides, one each for Bcl-2 and GPC3 staining. Following deparaffinisation in three changes of xylene and rehydration through descending grades of alcohol, antigen retrieval was performed in citrate buffer using an autoclave at 15 lbs pressure for 15 minutes. Endogenous peroxidase activity and non-specific protein binding were blocked using 3% hydrogen peroxide and protein-blocking reagent, respectively, for 10 minutes each. The sections were incubated with the respective primary antibodies according to the protocol used in the study. Subsequently, enhancer and streptavidin solutions were applied for 20 minutes each, followed by DAB chromogen for visualisation. The sections were counterstained with Mayer's haematoxylin, dehydrated, cleared in xylene and mounted with DPX. Appropriate positive and negative controls were included.
Positive controls were included for both markers: human tonsil tissue was used as the positive control for Bcl-2, showing the expected immunoreactivity in lymphoid cells, while hepatocellular carcinoma tissue was used as the positive control for GPC3, showing the expected tumour-cell immunoreactivity. Negative controls were processed by omitting the primary antibody.

Assessment of immunoreactivity

Immunostaining was evaluated by two observers in five randomly selected high-power fields at ×400 magnification. The parameters recorded were cellular localization, staining pattern, percentage of immunoreactive cells and staining intensity. Staining patterns were classified as absent, focal heterogeneous, reduced homogeneous or strong homogeneous. Percentage scores were: 0, no stained cells; 1, >0% to <10%; 2, 10% to <50%; 3, 50% to 80%; and 4, >80% positive cells. Intensity scores were: 0, no staining; 1, mild; 2, moderate; and 3, intense.
The final immunoreactive score was calculated by multiplying the percentage score (0–4) by the intensity score (0–3), yielding a possible range of 0–12. IRS categories were defined as 0–1, negative; 2–3, mild; 4–8,

moderate; and 9–12, strongly positive.

Statistical analysis

Data were compiled in Microsoft Excel and analysed using SPSS version 20.0 (SPSS Inc., Chicago, Illinois, USA). Categorical IRS distributions across the four independent study groups were compared using the Fisher–Freeman–Halton exact test for an r×c contingency table, with Monte Carlo estimation based on 200,000 conditional tables and the Pearson chi-square statistic as the ordering statistic. The analysis was performed separately for Bcl-2 and GPC3. The available dataset contained aggregate category counts only; therefore, case-level ordinal scores were unavailable for a Kruskal–Wallis test. A two-sided p-value <0.05 was considered statistically significant.

Ethical considerations

The study received approval from the Institutional Ethics Committee, Government Dental College and Hospital, Srinagar. The approval letter records the protocol review meeting date as 17 April 2026 and the approval reference as GDC/Perio/Eth Committee/41, dated 19 May 2026. The ethical approval was granted by the Institutional Ethics Committee.

RESULTS

The final dataset comprised 36 specimens: nine normal oral mucosal controls and 27 OSCC cases, equally distributed among WDSCC, MDSCC and PDSCC (nine cases per grade). All percentages are based on nine cases per group; therefore, one case corresponds to 11.1%.

Bcl-2 expression

The final Bcl-2 immunoreactive score (IRS) distribution was negative in 9/9 normal mucosal controls (100%), 5/9 WDSCC (55.6%), 1/9 MDSCC (11.1%) and 0/9 PDSCC. Mild IRS was recorded in 4/9 WDSCC (44.4%), 2/9 MDSCC (22.2%) and 2/9 PDSCC (22.2%). Moderate IRS was observed in 6/9 MDSCC (66.7%) and 3/9 PDSCC (33.3%). Strongly positive IRS was recorded in 4/9 PDSCC (44.4%). [Table 1].

In normal mucosa, the intensity-score chart records mild intensity in 5/9 cases; however, the percentage of immunoreactive cells was sufficiently low for the resulting IRS to remain within the prespecified negative category (IRS 0–1).

Bcl-2 IRS category	**NOM (n=9)**	**WDSCC (n=9)**	**MDSCC (n=9)**	**PDSCC (n=9)**
Negative	9 (100%)	5 (55.6%)	1 (11.1%)	0
Mild	0	4 (44.4%)	2 (22.2%)	2 (22.2%)
Moderate	0	0	6 (66.7%)	3 (33.3%)
Strongly positive	0	0	0	4 (44.4%)

Table 1. Final Bcl-2 immunoreactive score (IRS) distribution.

The Bcl-2 intensity-score distribution showed a shift towards stronger staining in the higher-grade groups. Staining was predominantly basal-cell in WDSCC, involved approximately half of the tumour islands in MDSCC and was more extensive in PDSCC. In normal mucosa, mild staining intensity was recorded in five cases, but the final IRS remained negative (0–1) in all nine controls because of the low percentage of positive cells.

The percentage-score distribution further demonstrated a progressive increase in the proportion of Bcl-2-positive tumour cells. In normal oral mucosa, 44.4% of cases had a percentage score of 0 and 55.6% had a score of 1. In WDSCC, scores 0, 1 and 2 were recorded in 11.1%, 55.6% and 33.3% of cases, respectively. In MDSCC, scores 1, 2 and 3 occurred in 11.1%, 66.7% and 22.2%, respectively. In PDSCC, scores 1, 2, 3 and 4 were observed in 11.1%, 22.2%, 33.3% and 33.3% of cases, respectively. Thus, the percentage of immunoreactive cells increased across the higher-grade groups, with a greater proportion of PDSCC cases showing staining in more than 50% of tumour cells.

Figure 1. Bcl-2 immunohistochemical photomicrographs

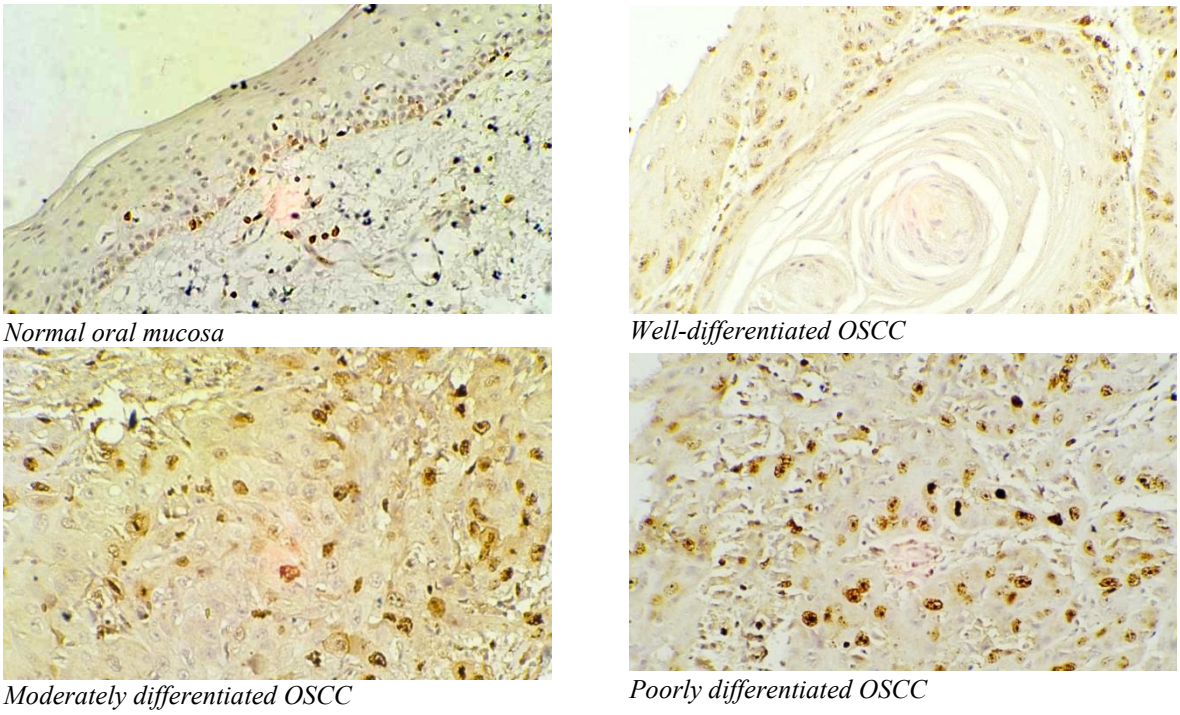

Figure 1.- *Immunohistochemical expression of Bcl-2 in normal oral mucosa and different histological grades of oral squamous cell carcinoma (OSCC). Normal oral mucosa shows predominantly mild and focal cytoplasmic immunoreactivity. Well-differentiated OSCC exhibits mild to moderate Bcl-2 expression, predominantly in the peripheral cells of tumour islands. Moderately differentiated OSCC demonstrates increased cytoplasmic immunoreactivity with moderate staining intensity. Poorly differentiated OSCC shows relatively strong and more diffuse cytoplasmic Bcl-2 expression in tumour cells. The photomicrographs demonstrate a progressive increase in Bcl-2 immunoreactivity with increasing histological grade of OSCC.*

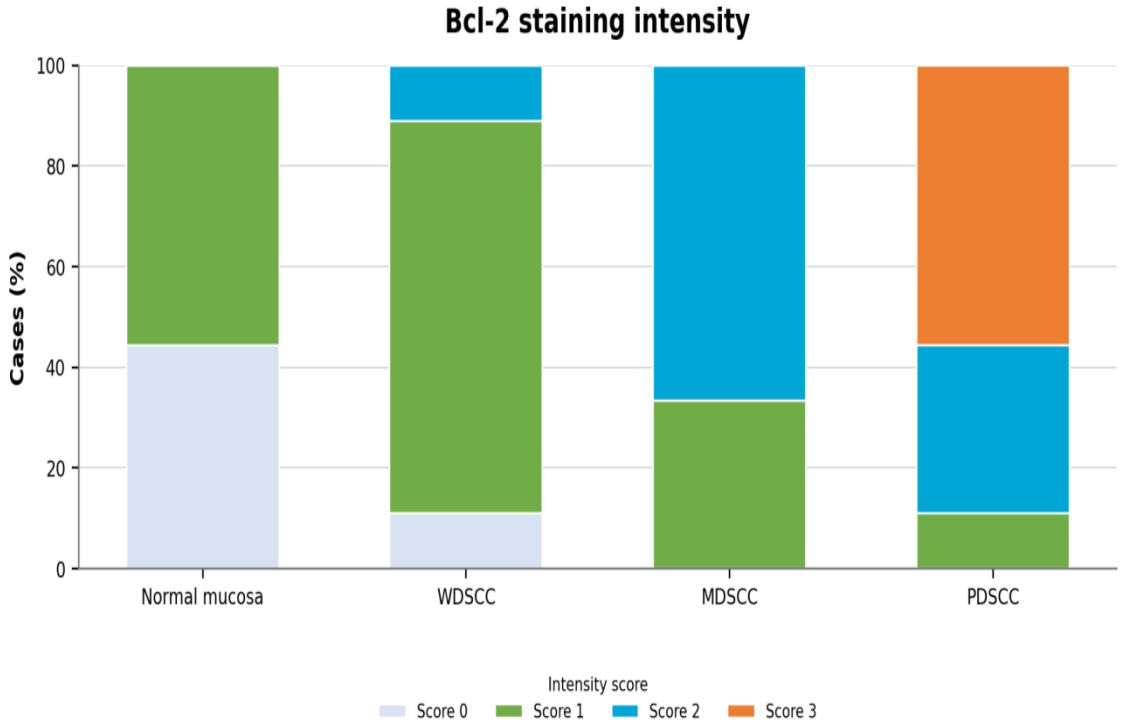

Graph 1-. *Bcl-2 staining intensity in normal oral mucosa, WDSCC, MDSCC and PDSCC (nine cases per group). Values are percentages of cases in each intensity-score category.*

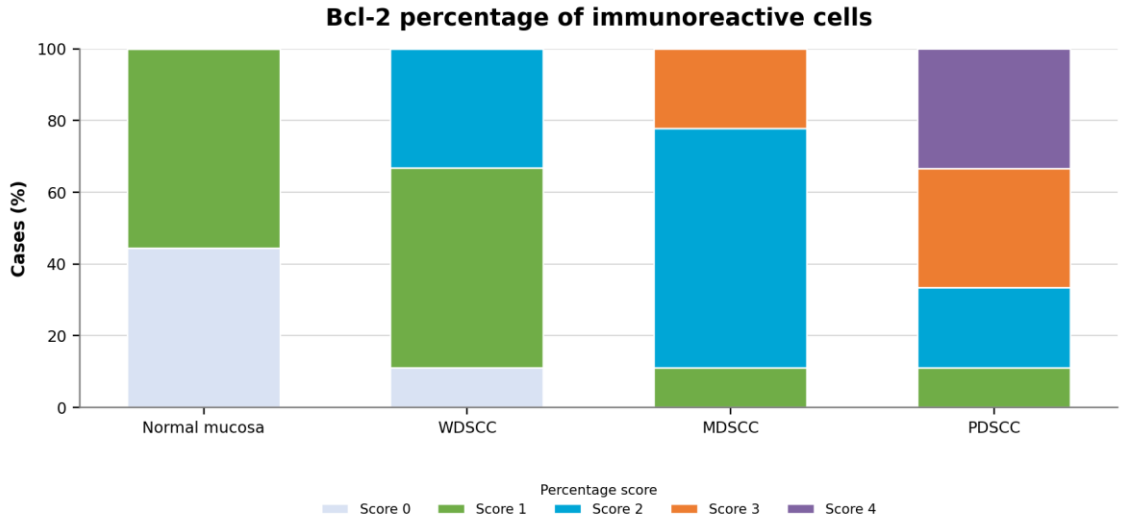

Graph 2 . Bcl-2 percentage of immunoreactive cells in normal oral mucosa, WDSCC, MDSCC and PDSCC (nine cases per group). Values are percentages of cases in each percentage-score category.

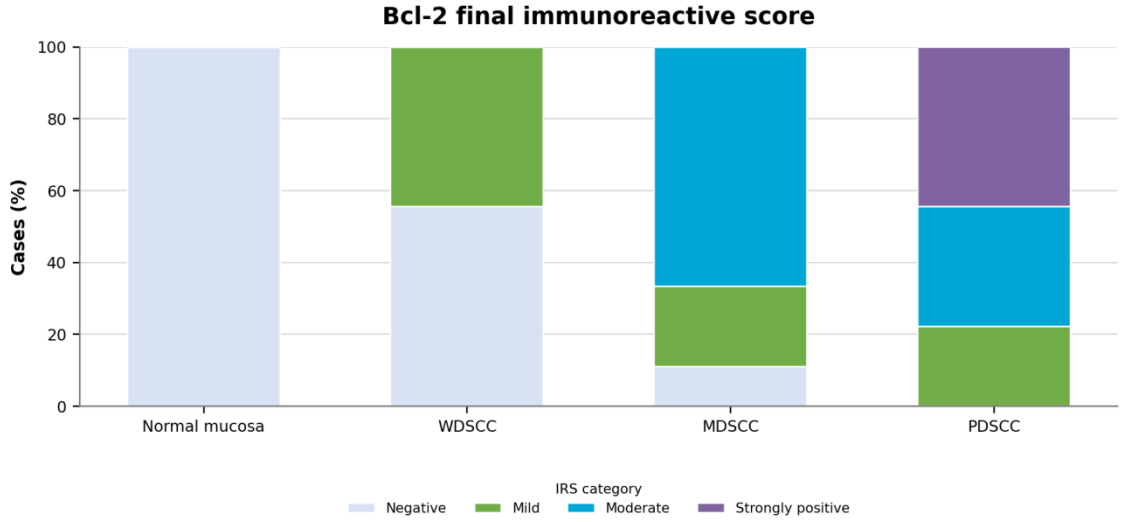

Graph 3- Bcl-2 final immunoreactive score in normal oral mucosa, WDSCC, MDSCC and PDSCC (nine cases per group). Values are percentages of cases in each IRS category.

GPC3 expression

GPC3 was negative in all nine normal mucosal controls. The final IRS distribution showed mild staining in 2/9 WDSCC cases (22.2%) and moderate staining in 7/9 (77.8%). In MDSCC, 8/9 cases (88.9%) showed moderate staining and 1/9 (11.1%) showed strong staining. In PDSCC, 3/9 cases (33.3%) showed moderate staining and 6/9 (66.7%) showed strong staining. The overall distribution differed significantly across the four groups. [Table 2]

GPC3 IRS category	NOM (n=9)	WDSCC (n=9)	MDSCC (n=9)	PDSCC (n=9)
Negative	9 (100%)	0	0	0
Mild	0	2 (22.2%)	0	0
Moderate	0	7 (77.8%)	8 (88.9%)	3 (33.3%)
Strongly positive	0	0	1 (11.1%)	6 (66.7%)

Table 2 - Final Bcl-2 immunoreactive score (IRS) distribution.

The GPC3 photomicrographs show no appreciable immunoreactivity in normal mucosa, mild staining predominantly in basal cells in WDSCC, moderate staining involving approximately half of the tumour islands in MDSCC, and intense staining in more than 60% of tumour islands in PDSCC.

The GPC3 staining-intensity graph showed score 0 in all normal mucosal controls (100%). In WDSCC, mild and moderate intensity (scores 1 and 2) were recorded in 11.1% and 88.9% of cases, respectively. MDSCC

showed moderate intensity in 66.7% and strong intensity (score 3) in 33.3% of cases. In PDSCC, 11.1% showed moderate intensity and 88.9% showed strong intensity. The percentage-score graph showed score 0 in all normal controls; in WDSCC, scores 1 and 2 occurred in 11.1% and 88.9%, respectively; in MDSCC, scores 2, 3 and 4 occurred in 55.6%, 33.3% and 11.1%, respectively; and in PDSCC, scores 2, 3 and 4 occurred in 22.2%, 44.4% and 33.3%, respectively. These distributions indicate progressively stronger staining and a larger proportion of GPC3-immunoreactive tumour cells in the higher-grade groups.

Figure 2. GPC3 immunohistochemical photomicrographs

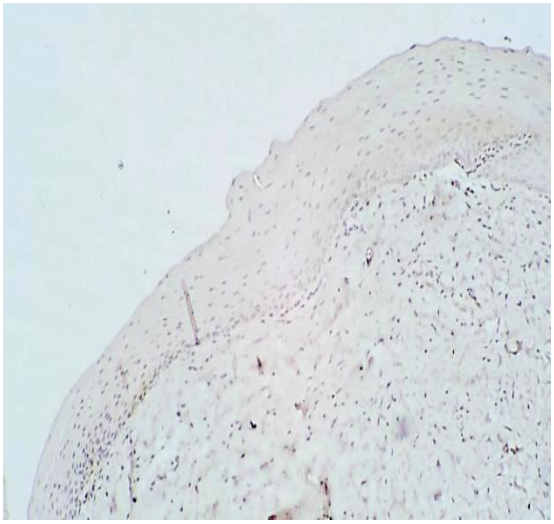

Normal oral mucosa

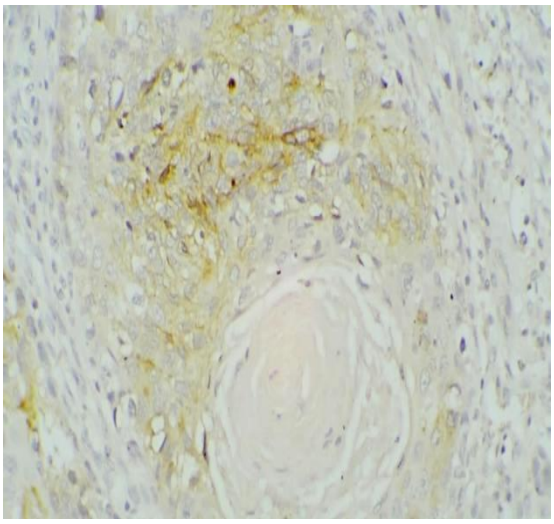

Well-differentiated OSCC

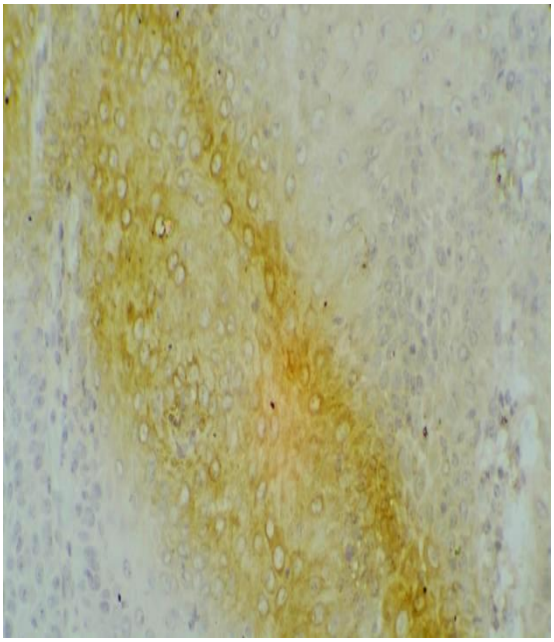

Moderately differentiated OSCC

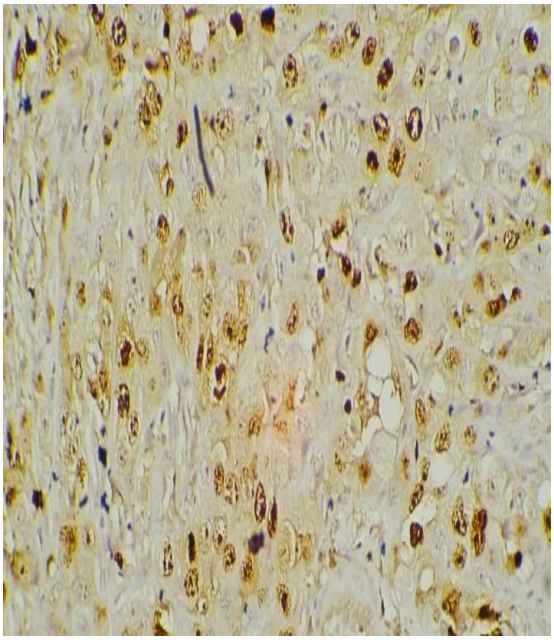

Poorly differentiated OSCC

Figure 2. *Immunohistochemical expression of Glypican-3 (GPC3) in normal oral mucosa and different histological grades of oral squamous cell carcinoma (OSCC). Normal oral mucosa shows absence of GPC3 immunoreactivity. Well-differentiated OSCC exhibits predominantly membranous staining, particularly at the periphery of tumour islands. Moderately differentiated OSCC demonstrates increased membranous and cytoplasmic immunoreactivity, whereas poorly differentiated OSCC shows intense and diffuse cytoplasmic as well as nuclear expression of GPC3 in tumour cells. The findings demonstrate a progressive increase in GPC3 expression with increasing histological grade of OSCC, accompanied by a shift in its cellular localization.*

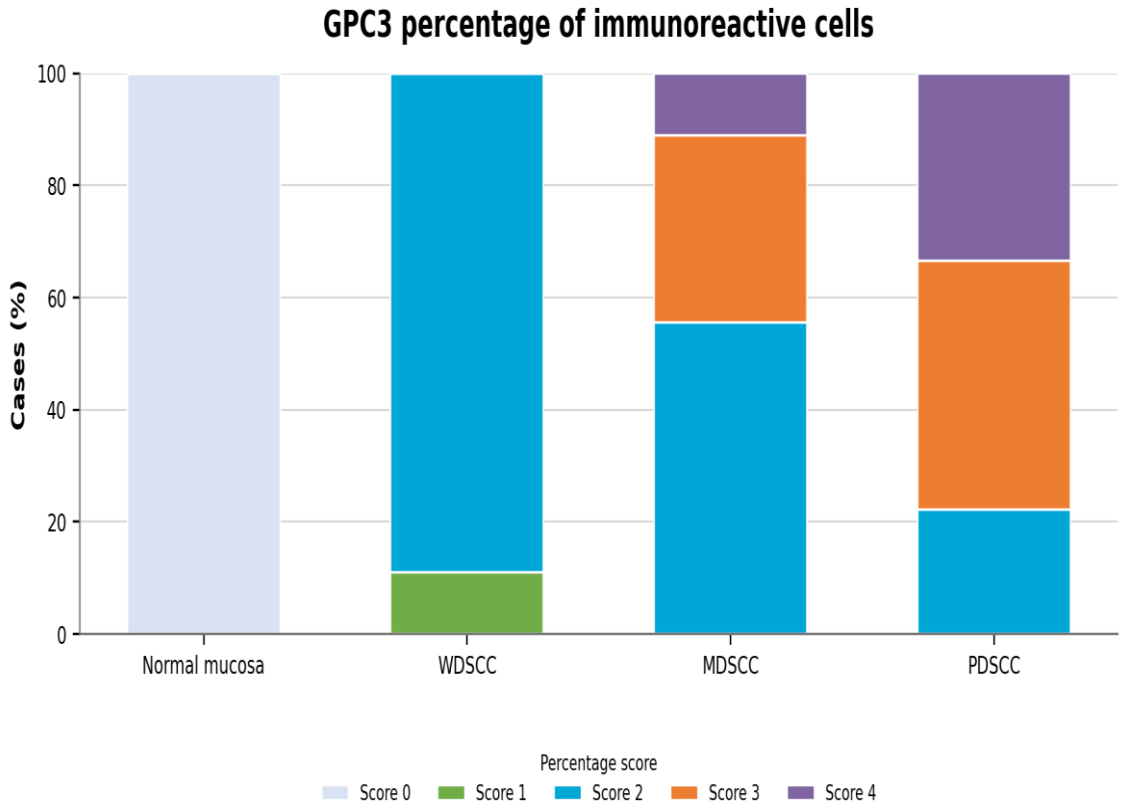

Graph 4- . GPC3 percentage of immunoreactive cells in normal oral mucosa, WDSCC, MDSCC and PDSCC (nine cases per group). Values are percentages of cases in each percentage-score category.

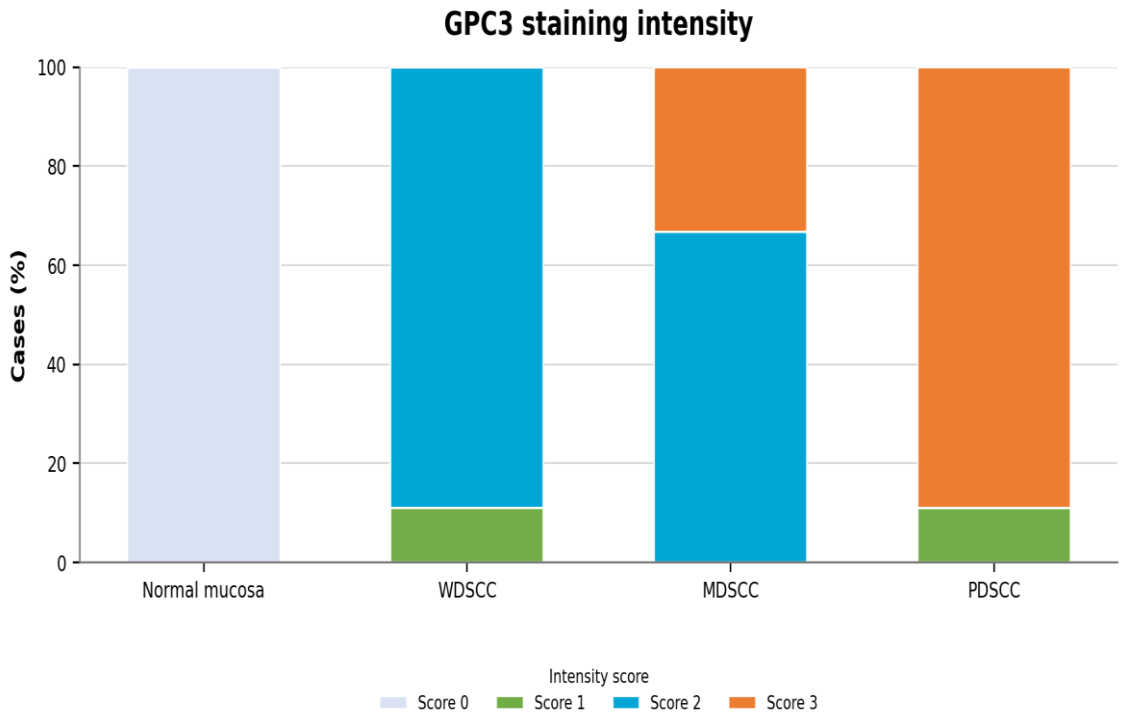

Graph 5- GPC3 staining intensity in normal oral mucosa, WDSCC, MDSCC and PDSCC (nine cases per group). Values are percentages of cases in each intensity-score category.

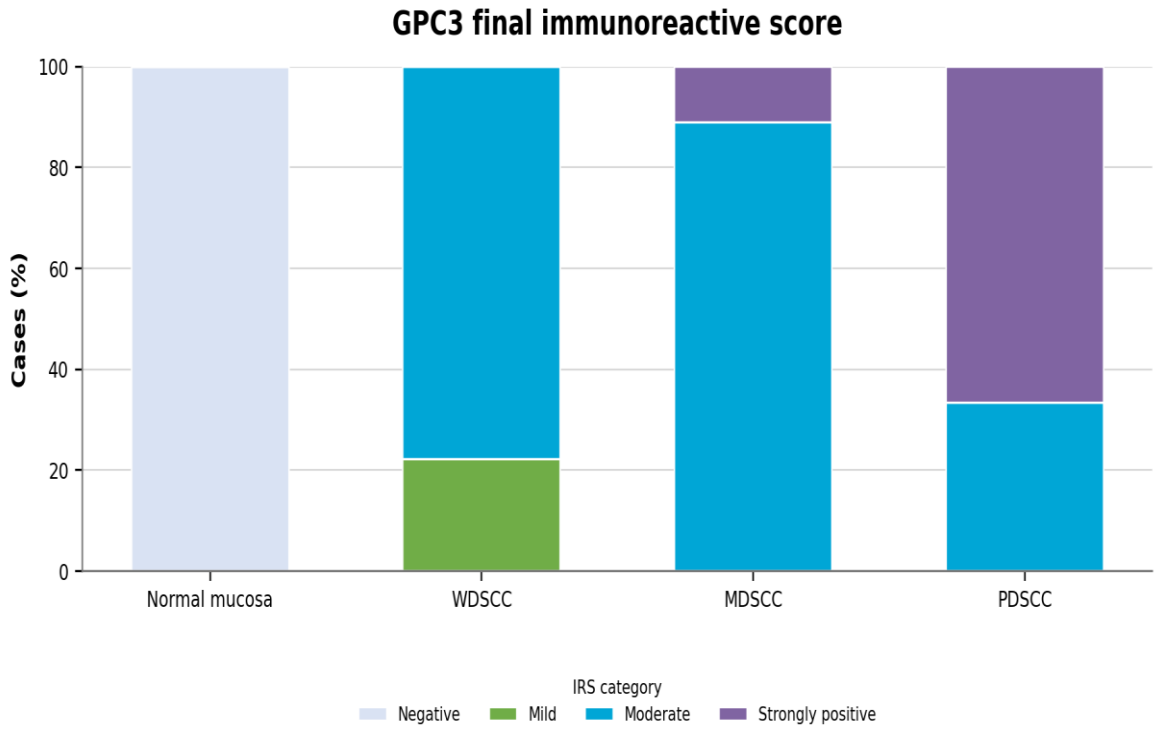

Graph 6.-. GPC3 final immunoreactive score in normal oral mucosa, WDSCC, MDSCC and PDSCC (nine cases per group). Values are percentages of cases in each IRS category.

Summary of the principal findings

Both markers showed a descriptive grade-wise shift towards higher IRS categories. For Bcl-2, strong IRS was confined to PDSCC (4/9 cases). For GPC3, strong IRS was observed in 1/9 MDSCC and 6/9 PDSCC cases. GPC3 was negative in all normal mucosal controls.

DISCUSSION

The present study compared Bcl-2 and GPC3 immunoexpression across normal oral mucosa and three histological grades of OSCC. The principal observation was a descriptive increase in the proportion of cases with moderate-to-strong IRS categories across the tumour-grade groups for both markers. GPC3 was negative in all normal mucosal controls, whereas moderate or strong staining was recorded in all OSCC grade groups. Bcl-2 showed a similar shift in the final IRS distribution, with strong staining identified in a subset of poorly differentiated carcinomas.

Glypican-3

The absence of GPC3 immunoreactivity in all normal mucosal controls is consistent with Andisheh-Tadbir et al., who reported negative GPC3 staining in non-neoplastic oral epithelium [12].

Schlaepfer-Sales et al. investigated GPC1, GPC3 and GPC5 at both transcript and protein levels in OSCC, tumour-free lateral margins and non-neoplastic mucosa [13].

In the present series, GPC3 IRS increased across the histological grades, with strong staining in two-thirds of PDSCC cases. This pattern is compatible with a possible association between GPC3 protein expression and tumour differentiation in this dataset, but it differs from the absence of a grade association reported by Andisheh-Tadbir et al. The small number of cases per grade, different antibody protocols, different positivity thresholds and potential intratumoural heterogeneity may explain some of the variation.

Bcl-2

Bcl-2 is an anti-apoptotic protein that can promote cell survival by inhibiting mitochondrial apoptotic signalling. In the present series, the final IRS distribution shifted from predominantly negative staining in normal mucosa and WDSCC towards moderate and strong staining in MDSCC and PDSCC. This finding may indicate altered regulation of apoptosis in OSCC, but immunohistochemical expression alone does not establish functional inhibition of apoptosis. [4–7]

The Bcl-2 findings should be interpreted in light of conflicting published evidence. Garewal et al. examined 30 OSCC cases and reported a statistically significant decrease in Bcl-2 expression from well- to moderately- to poorly differentiated OSCC [8]. Munjal et al., in a 70-sample study including normal mucosa, oral potentially malignant disorders and OSCC, described higher basal/parabasal expression in normal mucosa with a progressive decrease in OPMD and OSCC [9].

Strengths and limitations

A strength of the study is the inclusion of an equal number of cases in each of four groups and the assessment

of two biologically distinct markers using a defined percentage-by-intensity scoring framework. Two observers assessed five high-power fields per case.

- The sample size was small (nine cases per group), limiting precision and generalizability.
- The study was retrospective and relied on archival tissue; selection and information biases cannot be excluded.

CONCLUSION

The present study demonstrated a progressive increase in Bcl-2 immunoreactivity from normal oral mucosa and WDSCC to MDSCC and PDSCC, suggesting a possible role in tumour cell survival through inhibition of apoptosis. GPC3 was negative in all normal mucosal controls but showed increasing staining intensity, percentage positivity and IRS across OSCC grades, with strong expression in 66.7% of PDSCC cases. Both markers may serve as complementary adjunctive markers for evaluating OSCC biology; however, their diagnostic, prognostic and therapeutic significance requires confirmation through larger studies using standardised methods, multiple molecular markers and clinical follow-up.

Acknowledgment: The authors acknowledge Government Dental College and Hospital, Srinagar, Jammu & Kashmir – 190010.
Financial support and sponsorship: Nil.
Conflicts of interest: There are no conflicts of interest.
Data availability: The data supporting this study are available from the corresponding author subject to institutional permissions.

REFERENCES

1. Sung H, Ferlay J, Siegel RL, Laversanne M, Soerjomataram I, Jemal A, et al. Global cancer statistics 2020: GLOBOCAN estimates of incidence and mortality worldwide for 36 cancers in 185 countries. CA Cancer J Clin. 2021;71(3):209-49. doi:10.3322/caac.21660.
2. El-Naggar AK, Chan JKC, Grandis JR, Takata T, Slootweg PJ, editors. WHO classification of head and neck tumours. 5th ed. Lyon: International Agency for Research on Cancer; 2022.
3. Tsujimoto Y, Cossman J, Jaffe E, Croce CM. Involvement of the bcl-2 gene in human follicular lymphoma. Science. 1985;228(4706):1440-3.
4. Korsmeyer SJ. Bcl-2 initiates a new category of oncogenes: regulators of cell death. Blood. 1992;80(4):879-86.
5. Reed JC. Bcl-2 family proteins. Oncogene. 1998;17(25):3225-36.
6. Youle RJ, Strasser A. The BCL-2 protein family: opposing activities that mediate cell death. Nat Rev Mol Cell Biol. 2008;9(1):47-59.
7. Adams JM, Cory S. The Bcl-2 apoptotic switch in cancer development and therapy. Oncogene. 2007;26(9):1324-37.
8. Garewal J, Garewal R, Sircar K. Expression of Bcl-2 and MIB-1 markers in oral squamous cell carcinoma (OSCC)—a comparative study. J Clin Diagn Res. 2014;8(7):QC01-4. doi:10.7860/JCDR/2014/6474.4562.
9. Munjal MK, Ramalingam K, Sihmar SS, Gill K, Khan MI. BCL2 expression in OPMD and OSCC—an immunohistochemical study on 70 samples. J Pharm Negative Results. 2022;13(Spec Issue 4):1177-91. doi:10.47750/pnr.2022.13.S04.138.
10. Filmus J, Selleck SB. Glypicans: proteoglycans with a surprise. J Clin Invest. 2001;108(4):497-501.
11. Capurro MI, Xiang YY, Lobe C, Filmus J. Glypican-3 promotes the growth of hepatocellular carcinoma by stimulating canonical Wnt signaling. Cancer Res. 2005;65(14):6245-54.
12. Andisheh-Tadbir A, Goharian AS, Ranjbar MA. Glypican-3 expression in patients with oral squamous cell carcinoma. J Dent (Shiraz). 2020;21(2):141-6. doi:10.30476/DENTJODS.2019.84541.1089.
13. Schlaepfer-Sales CB, Guimarães VSN, Valverde LF, Dias RB, Freitas RD, Siquara da Rocha LO, et al. Glypican-1, -3, -5 (GPC1, GPC3, GPC5) and Hedgehog pathway expression in oral squamous cell carcinoma. Appl Immunohistochem Mol Morphol. 2021;29(5):345-51. doi:10.1097/PAI.0000000000000907.
14. von Elm E, Altman DG, Egger M, Pocock SJ, Gøtzsche PC, Vandenbroucke JP; STROBE Initiative. The Strengthening the Reporting of Observational Studies in Epidemiology (STROBE) statement: guidelines for reporting observational studies. PLoS Med. 2007;4(10):e296. doi:10.1371/journal.pmed.0040296.