GMR
The Original

PAPILLARY THYROID CARCINOMA CONFINED TO A THYROGLOSSAL DUCT CYST: A CASE REPORT

Ziyad A Almushayti[1*]

[1*]Department of Radiology, College of Medicine, Qassim University, Buraydah, 52571, Saudi Arabia, ziyadalmushayti@qu.edu.sa
***Corresponding Author**: Dr. Ziyad A Almushayti, E-mail: ziyadalmushayti@qu.edu.sa

Received: June 03, 2026; Revised: August 27, 2026; Accepted: September 05, 2026; Available Online: September 14, 2026

ABSTRACT:
Introduction: Papillary thyroid carcinoma (PTC) is the most common malignant histological subtype reported within a thyroglossal duct cyst (TGDC), with malignant transformation occurring in approximately 1% of cases. In this case, a 42-year-old man presented with a six-month history of a gradually enlarging midline anterior neck mass. Clinical findings: Examination revealed a smooth, non-tender mass at the level of the hyoid bone that moved with swallowing and tongue protrusion. Imaging demonstrated a mixed cystic-solid mass with internal calcifications and no evidence of local invasion or cervical lymphadenopathy. Fine-needle aspiration was non-diagnostic. Main diagnosis: Following Sistrunk surgery, histopathological examination demonstrated papillary thyroid carcinoma confined to the cyst wall, with no extension into surrounding tissues or lymphovascular invasion. Postoperative thyroid ultrasonography showed no suspicious thyroid lesion, and thyroid function tests were within normal limits. Conclusion: This case demonstrates the rare occurrence of PTC arising within a TGDC and highlights the importance of complete surgical excision and careful histopathological assessment, even when clinical findings are not overtly suggestive of malignancy.

KEYWORDS: Thyroglossal Duct Cyst (TGDC), Papillary Thyroid Carcinoma (PTC), Midline Neck Mass, Sistrunk Procedure, Ultrasound, Computed Tomography.

INTRODUCTION

Thyroglossal duct cysts (TGDCs) are among the most common congenital midline neck lesions and result from incomplete involution of the thyroglossal duct. Although usually benign and often identified in childhood, they may also present in adults. Malignant transformation is rare, occurring in approximately 1% of cases, and papillary thyroid carcinoma (PTC) is the most common histological subtype [1]. Preoperative diagnosis of TGDC carcinoma can be challenging because its clinical appearance often resembles that of a benign cyst. Malignancy is therefore frequently identified only after surgical excision and histopathological examination. Imaging with ultrasound and computed tomography may raise suspicion when solid mural components or internal calcifications are present, while fine-needle aspiration may be non-diagnostic in predominantly cystic lesions [2,7,9-11].
The Sistrunk procedure, which removes the cyst, the central portion of the hyoid bone, and the thyroglossal tract, is the standard surgical treatment for TGDC. In selected patients with carcinoma confined to the cyst, no cervical lymph-node involvement, and no suspicious thyroid lesion, the Sistrunk procedure alone may be sufficient, whereas additional thyroid-directed treatment is considered according to individual risk factors and clinical findings [2-6,9,11]. This case report describes papillary thyroid carcinoma arising within a TGDC in a patient from the Al-Qassim region of Saudi Arabia, with the malignancy confined to the cyst wall and no evidence of local invasion or regional lymph-node metastasis. The case highlights the diagnostic limitations of preoperative assessment and the potential role of conservative surgical management in selected patients with localized TGDC carcinoma.

Case Report of Patient

Patient Demographics

The patient was a 42-year-old man who worked in an office. He had no history of previous neck surgery or therapeutic radiation exposure and no known family history of thyroid malignancy or other endocrine disorders.

Clinical Case Representation

Primary Complaint and Mass Characteristics

The patient presented with a midline anterior neck mass first noticed six months before clinical evaluation. The lesion had gradually increased in size and measured approximately 3 cm at the time of examination.

Associated and Local Symptoms

The patient reported mild discomfort during swallowing but no hoarseness, dyspnea, significant dysphagia, or pain.

Systemic Evaluation

There was no history of unintentional weight loss, fever, or persistent fatigue.

Detailed Clinical Assessment and Examination

Inspection and Palpation

Examination revealed a smooth, well-defined, firm, non-tender midline neck mass at the level of the hyoid bone, with no overlying erythema, scarring, or sinus tract.

A characteristic clinical feature was observed:

The mass moved vertically with both swallowing and tongue protrusion, a characteristic finding of a thyroglossal duct lesion.

Thyroid and Lymphatic Evaluation:

The thyroid gland was clinically normal in size and texture, with no palpable nodules or goiter. No cervical lymphadenopathy was identified.

Imaging Findings

Contrast-enhanced CT of the neck demonstrated a midline mixed cystic-solid lesion in the anterior neck, closely related to the hyoid bone. The lesion contained internal microcalcifications.

The thyroid gland, trachea, and adjacent musculature were preserved, with no evidence of local invasion. No suspicious cervical lymph nodes were identified.

Clinical Investigation and Management Summary

The clinical evaluation progressed from initial aspiration to definitive surgical excision and histopathological assessment:

Preoperative fine-needle aspiration (FNA)

Fine-needle aspiration was performed as the initial diagnostic procedure. It yielded acellular cystic fluid and was therefore non-diagnostic.

Surgical Excision and Histopathology

A Sistrunk procedure was performed because of the progressive enlargement of the mass. The cyst, central portion of the hyoid bone, and thyroglossal tract were removed en bloc. Histopathological examination of the specimen demonstrated:

- Diagnosis: Papillary thyroid carcinoma (PTC) confined to the thyroglossal duct cyst wall.
- Cellular features: Classic features of PTC were identified, including nuclear grooves and intranuclear pseudoinclusions.
- Invasion status: No extension beyond the cyst wall and no lymphovascular invasion were identified.

Postoperative Assessment

A postoperative evaluation was performed to assess the thyroid gland for a synchronous lesion:

- Thyroid ultrasonography: Normal thyroid parenchyma with no suspicious nodules.
- Thyroid function tests: The patient was euthyroid, with TSH and free T4 levels within the laboratory reference ranges.
- Serum thyroglobulin: The serum thyroglobulin level was within the laboratory reference range.

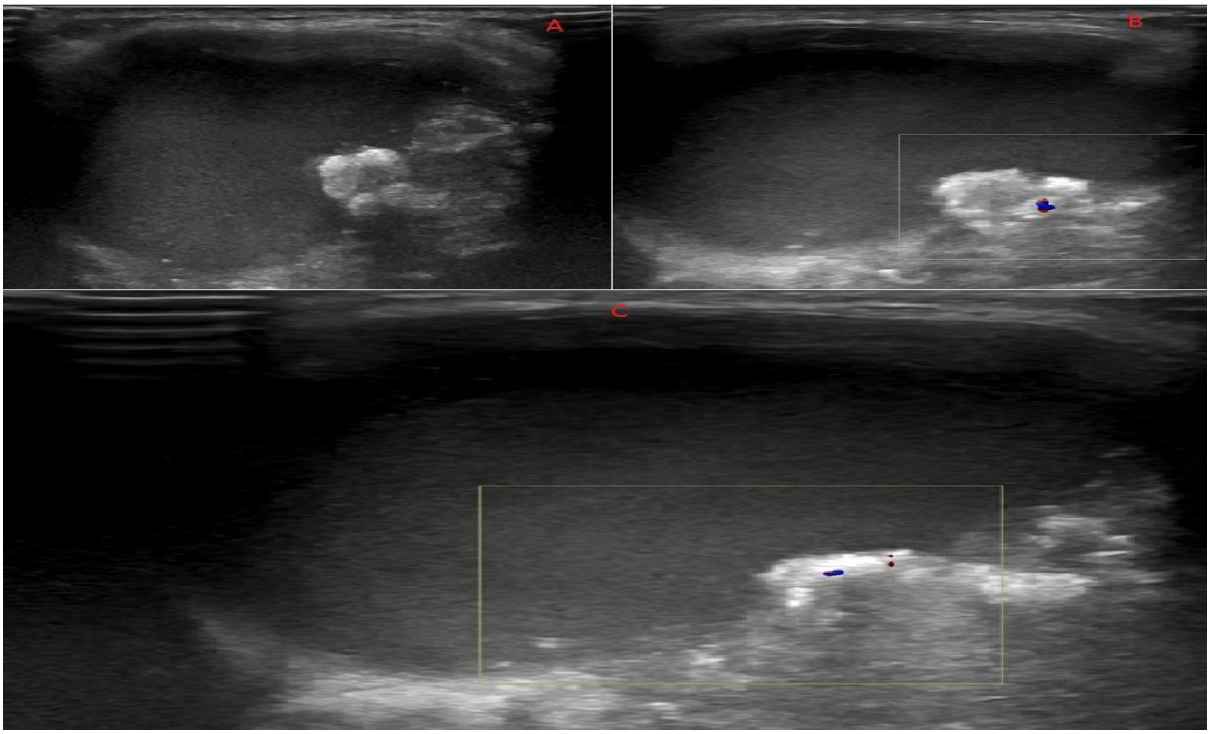

Figure 1. Neck ultrasonography demonstrated a cystic lesion at the level of the hyoid bone (A), containing a hyperechoic solid component with calcific foci. Color Doppler images (B and C) demonstrated vascularity within the solid component.

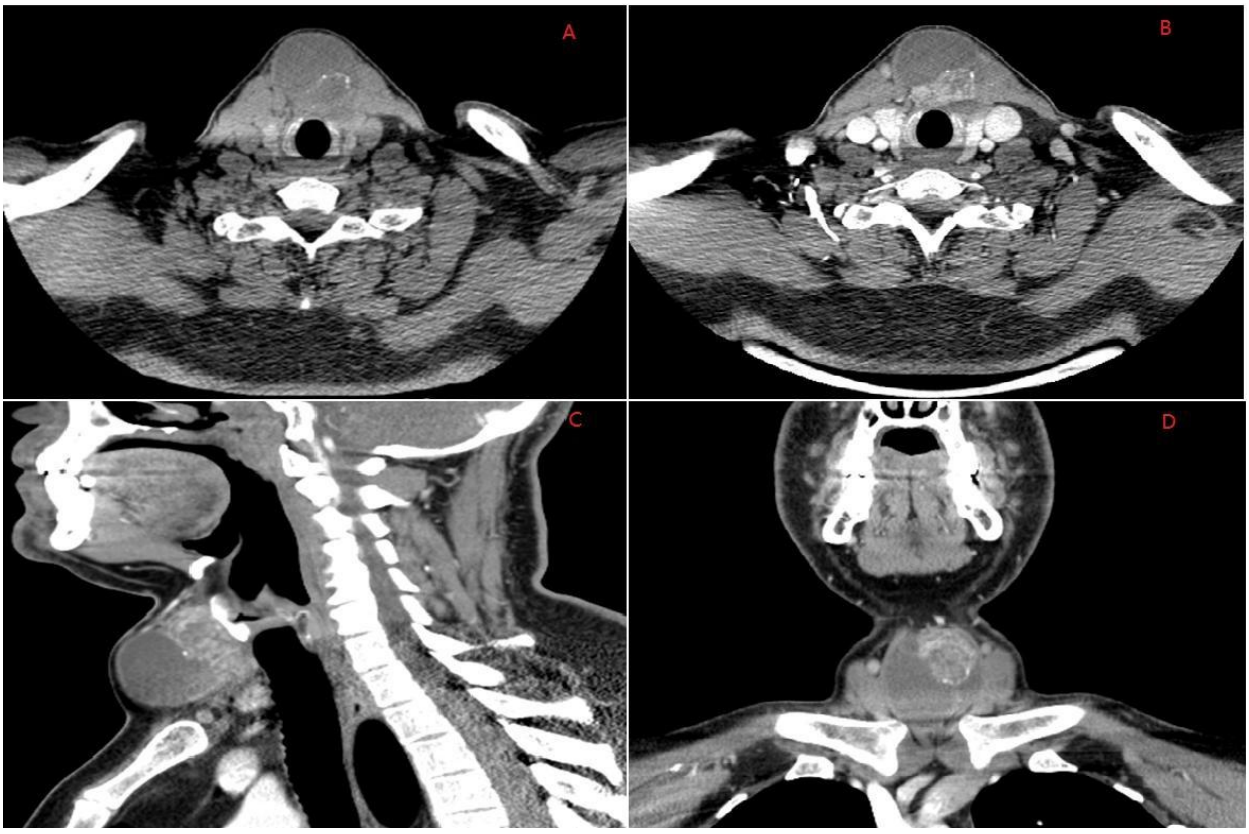

Figure 2. Neck CT examination (A-D): pre-contrast axial image (A) demonstrates a midline cystic lesion anterior to the thyroid cartilage with internal microcalcifications. Post-contrast axial (B), sagittal (C), and coronal (D) images demonstrate avid enhancement of the solid component.

CT imaging demonstrates the relationship of the lesion to the surrounding neck structures and assists in surgical planning.

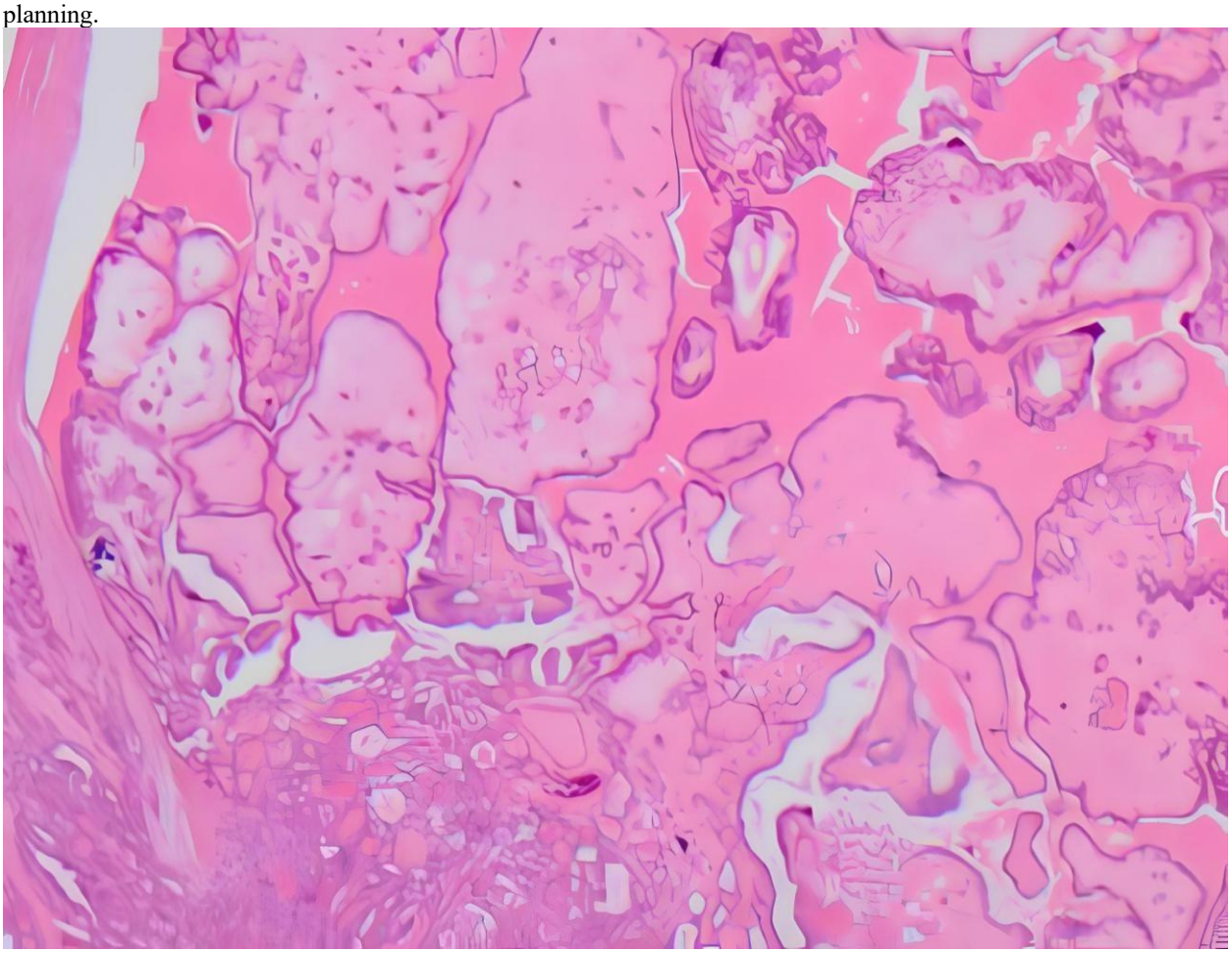

Figure 3. Histopathological features of papillary thyroid carcinoma (PTC) within the thyroglossal duct cyst wall.

Microscopic findings
Histopathological examination demonstrated papillary thyroid carcinoma confined to the thyroglossal duct cyst wall, without invasion of the surrounding tissues.
Architectural features: Malignant follicular epithelial cells formed papillary projections supported by fibrovascular cores, with growth confined to the cyst lining.
Nuclear morphology: Diagnostic features of PTC included:
• Nuclear clearing with fine, dispersed chromatin
• Nuclear grooves
• Intranuclear pseudoinclusions
Psammoma bodies were identified within the papillary cores.
Invasion status: The tumor was confined to the cyst wall, with no lymphovascular invasion or extension into surrounding tissues.

Discussion and Literature Analysis

Papillary thyroid carcinoma arising within a thyroglossal duct cyst is uncommon, occurring in approximately 1% of TGDC cases. In this case, a 42-year-old man presented with a gradually enlarging midline neck mass that moved with tongue protrusion, initially resembling a benign TGDC. Histopathological examination after Sistrunk excision demonstrated PTC confined to the cyst wall, with no lymphovascular invasion or extension into surrounding tissues [14-15].

Comparison of Diagnostic Modalities

The diagnostic course in this case reflects challenges frequently described in the literature [15-17]:

- Imaging: CT demonstrated a mixed cystic-solid lesion with internal microcalcifications. Solid mural components and calcifications are imaging features that may raise suspicion for malignancy.
- FNA limitations: Fine-needle aspiration was non-diagnostic because it yielded acellular cystic fluid. This limitation has been described in cystic neck lesions, where malignant foci may not be adequately sampled.
- Surgical management: The Sistrunk procedure provided both definitive excision and sufficient tissue for histopathological diagnosis when preoperative cytology was inconclusive.

Analysis of Tumor Origin and Management

Whether PTC identified in a TGDC represents a primary carcinoma arising from ectopic thyroid tissue or disease associated with an occult thyroid primary remains an important consideration. In this case, several findings supported a localized TGDC lesion [17-18]:

- Localized pathology: Histological examination showed PTC confined to the cyst wall, with no lymphovascular invasion or extension into surrounding tissues.
- Thyroid evaluation: Postoperative thyroid ultrasonography demonstrated normal parenchyma with no suspicious nodules.
- Clinical implications: Published clinical series suggest that when the thyroid gland is radiologically normal and the carcinoma is confined to the TGDC, the Sistrunk procedure alone may be considered adequate in selected patients, without routine total thyroidectomy or radioactive iodine therapy.

Diagnostic Challenges and Imaging

Preoperative diagnosis of TGDC carcinoma remains challenging. In this case, fine-needle aspiration was non-diagnostic, while CT demonstrated a mixed cystic-solid lesion with internal microcalcifications, imaging features that may raise suspicion for malignancy. This highlights the dual diagnostic and therapeutic role of the Sistrunk procedure when preoperative cytology is inconclusive [19-20].
Histopathological examination following the Sistrunk procedure demonstrated PTC confined to the cyst wall, with no lymphovascular invasion, extension into surrounding tissues, or cervical lymphadenopathy. Postoperative thyroid ultrasonography demonstrated no suspicious lesion within the thyroid gland. Because the thyroid remained intact, a normal serum thyroglobulin level was not considered sufficient to exclude occult thyroid carcinoma. Accordingly, it is more appropriate to state that no synchronous thyroid lesion was identified on postoperative ultrasonography.

CONCLUSION

Papillary thyroid carcinoma arising within a thyroglossal duct cyst is rare and may be clinically indistinguishable from a benign TGDC. The presence of a solid component and internal calcifications should raise suspicion for malignancy, although definitive diagnosis may only be established after histopathological examination. In selected patients with carcinoma confined to the cyst wall, no cervical lymphadenopathy, and no suspicious thyroid lesion, the Sistrunk procedure may represent adequate initial management. In this patient, no additional thyroid-directed treatment was undertaken because the carcinoma was confined to the cyst wall, there was no cervical lymphadenopathy, and postoperative thyroid ultrasonography showed no suspicious lesion. Long-term clinical and sonographic follow-up remains important.

Study Limitation

This report describes a single patient and therefore cannot establish the comparative effectiveness of different treatment strategies or provide generalizable estimates of recurrence or prognosis. The absence of a control group and the limitations inherent to a single case restrict conclusions regarding long-term outcomes. Larger multicenter studies with longer follow-up are needed to better define risk stratification and optimal management of TGDC carcinoma.

Ethical Approval
This study was approved by the Regional Research Ethics Committee (Approval No. 607-48-002097), registered at the National Committee of Bio & Med. Ethics (NCBE), Registration No. H-04-Q-001, Qassim Province, Ministry of Health, Saudi Arabia. Written informed consent was obtained from the patient prior to inclusion in the study. All patient data were anonymized to ensure confidentiality.

Conflict of Interest
The author declares no conflict of interest, financial or otherwise.

Funding
This study received no external or internal funding.

REFERENCES

[1] Alrohaimi, F. A., Alqahtani, S. M., & Almutairi, A. B. (2024). Thyroglossal Duct Cyst Papillary Carcinoma: A Rare Disease Entity. *Cureus*, *16*(10), e70999. https://doi.org/10.7759/cureus.70999.

[2] Gómez-Álvarez, L. R., Treviño-Lozano, M. A., de la O-Escamilla, M. E., Vergara-Miranda, H., Anda, L. A. M., Falcón, L. Á. C., & Tafoya, A. R. (2022). Papillary thyroid carcinoma from a thyroglossal cyst: case series. *Journal of surgical case reports*, *2022*(2), rjab613. https://doi.org/10.1093/jscr/rjab613.

[3] Shah, V. S., Vaidya, R. U., Desai, S. C., & Gajjar, J. P. (2024). Papillary Carcinoma Within a Thyroglossal Duct Cyst. *Cureus*, *16*(11), e74407. https://doi.org/10.7759/cureus.74407.

[4] Van Beck, J., & Khaja, S. F. (2019). Thyroglossal Duct Cyst Carcinoma in a Young Female: Case Report and Review of Literature. *Case reports in otolaryngology*, *2019*, 4069375. https://doi.org/10.1155/2019/4069375.

[5] Saavedra-Leveau, J. L., Chang-Grozo, S. L., Dominguez-Prado, M. E., & Ticona-Zegarra, L. A. (2021). "Incidental Papillary Thyroid Cancer in Thyroglossal Duct Cyst": A Case Report. *Iranian journal of otorhinolaryngology*, *33*(116), 187–190. https://doi.org/10.22038/ijorl.2021.46922.2565

[6] Srivanitchapoom, C., Sittitrai, P., Yata, K., & Khongpiboonkit, P. (2017). Ultrasonographic findings of thyroglossal duct papillary carcinoma: A case report. *International journal of surgery case reports*, *32*, 54–57. https://doi.org/10.1016/j.ijscr.2017.02.007.

[7] Seo, D. H., Lee, S. G., Lee, H. Y., Jeong, S., Park, S., Lee, J., & Jo, Y. S. (2023). Lymph node metastasis-dependent molecular classification in papillary thyroid carcinoma defines aggressive metastatic outgrowth. *Clinical and translational medicine*, *13*(3), e1211. https://doi.org/10.1002/ctm2.1211.

[8] Alatsakis, M., Drogouti, M., Tsompanidou, C., Katsourakis, A., & Chatzis, I. (2018). Invasive Thyroglossal Duct Cyst Papillary Carcinoma: A Case Report and Review of the Literature. *The American journal of case reports*, *19*, 757–762. https://doi.org/10.12659/AJCR.907313.

[9] Pellegriti, G., Lumera, G., Malandrino, P., Latina, A., Masucci, R., Scollo, C., Spadaro, A., Sapuppo, G., Regalbuto, C., Pezzino, V., & Vigneri, R. (2013). Thyroid cancer in thyroglossal duct cysts requires a specific approach due to its unpredictable extension. *The Journal of clinical endocrinology and metabolism*, *98*(2), 458–465. https://doi.org/10.1210/jc.2012-1952.

[10] Yanar, C., Cetinoglu, I., Sengul, Z., Caliskan, O., Taner Unlu, M., Aygun, N., & Uludag, M. (2024). Coexistence of Thyroglossal Cyst and Thyroid Disease in Adults: Surgical Outcomes From A Single Center. *Sisli Etfal Hastanesi tip bulteni*, *58*(3), 291–297. https://doi.org/10.14744/SEMB.2024.99390.

[11] Solis-Pazmino, P., Figueroa, L., Pilatuña, E. A., Rocha, C., Godoy, R., & García, C. (2023). Surgical approach for thyroglossal duct cyst cancer: a case report of challenging conventional thinking. *Journal of surgical case reports*, *2023*(8), rjad448. https://doi.org/10.1093/jscr/rjad448.

[12] Thompson, L. D. R., Herrera, H. B., & Lau, S. K. (2017). Thyroglossal Duct Cyst Carcinomas: A Clinicopathologic Series of 22 Cases with Staging Recommendations. *Head and neck pathology*, *11*(2), 175–185. https://doi.org/10.1007/s12105-016-0757-y

[13] Amin, M. B., Greene, F. L., Edge, S. B., Compton, C. C., Gershenwald, J. E., Brookland, R. K., Meyer, L., Gress, D. M., Byrd, D. R., & Winchester, D. P. (2017). The Eighth Edition AJCC Cancer Staging Manual: Continuing to build a bridge from a population-based to a more "personalized" approach to cancer staging. *CA: a cancer journal for clinicians*, *67*(2), 93–99. https://doi.org/10.3322/caac.21388.

[14] Shemen, L., Sherman, C. H., & Yurovitsky, A. (2016). Imaging characteristics and findings in thyroglossal duct cyst cancer and concurrent thyroid cancer. *BMJ case reports*, *2016*, bcr2016215059. https://doi.org/10.1136/bcr-2016-215059.

[15] Iftikhar, H., Ikram, M., Rizwan Nathani, K., & Yar Muhammad, A. (2018). Papillary Thyroid Carcinoma within Thyroglossal Duct Cyst: Case Series and Literature Review. *International archives of otorhinolaryngology*, *22*(3), 253–255. https://doi.org/10.1055/s-0037-1606277.

[16] Alqahtani, S. M., Rayzah, M., Al Mutairi, A., Alturiqy, M., Hendam, A., & Bin Makhashen, M. (2022). Papillary carcinoma arising from a thyroglossal duct cyst: A case report and literature review. *International journal of surgery case reports*, *94*, 107106. https://doi.org/10.1016/j.ijscr.2022.107106

[17] Ogunkeyede, S. A., & Ogundoyin, O. O. (2019). Management outcome of thyroglossal cyst in a tertiary health center in Southwest Nigeria. *The Pan African medical journal*, *34*, 154. https://doi.org/10.11604/pamj.2019.34.154.18765

[18] Wood, C. B., Bigcas, J. L., Alava, I., Bischoff, L., Langerman, A., & Kim, Y. (2018). Papillary-Type Carcinoma of the Thyroglossal Duct Cyst: The Case for Conservative Management. *The Annals of otology, rhinology, and laryngology*, *127*(10), 710–716. https://doi.org/10.1177/0003489418791892.

[19] Bahar, A., Torabizadeh, Z., Movahedi Rad, M., & Kashi, Z. (2020). Papillary carcinoma in correlation to thyroidal duct cyst: A case series. *Caspian journal of internal medicine*, *11*(1), 110–115. https://doi.org/10.22088/cjim.11.1.110.
[20] Murgod, P. S., Jaison, J., Dhande, S., & Bhide, S. (2024). Papillary Thyroid Carcinoma within a Thyroglossal Cyst: A Rare Case Report with Review of Literature. *Indian journal of otolaryngology and head and neck surgery: official publication of the Association of Otolaryngologists of India*, *76*(1), 1101–1105. https://doi.org/10.1007/s12070-023-04141-1.