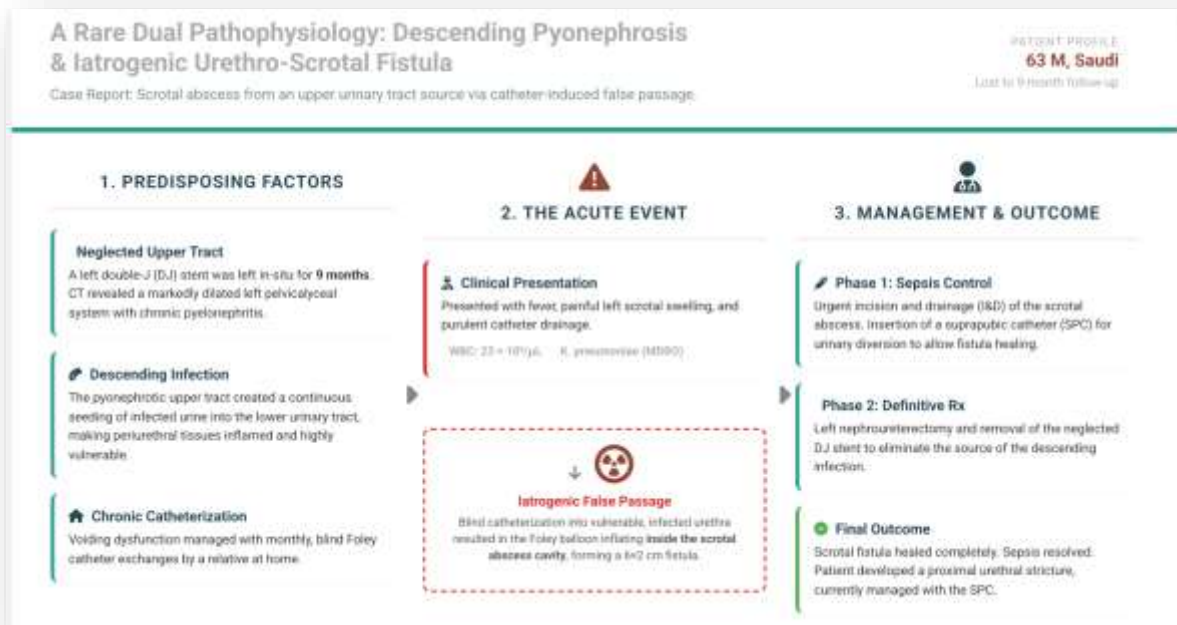

## Urinary Catheter-Induced Urethro-Scrotal Fistula With Scrotal Abscess From A Descending Pyonephrotic Infection: A Case Report

Mohammed M Aljohani

Assistant Professor of Urology, Department of Surgery, Faculty of Medicine, University of Tabuk; Urology and Endourology Consultant, King Fahad Specialist Hospital, Tabuk, Saudi Arabia.  
 m.maljohani@ut.edu.sa  
 Orcid:0009-0007-6035-0925

### Graphic abstract



## Abstract

**Background:** Scrotal abscesses are typically caused by local or ascending genitourinary infections, with chronic Foley catheter use being a well-established risk factor. Urethro-scrotal fistula (USF) is a rare complication that may be iatrogenic or secondary to trauma. However, a descending infection from an upper urinary tract source leading to catheter-induced fistula formation has not been previously described.

**Case Presentation:** A 63-year-old Saudi male with a history of left pyelonephritis and difficult double-J (DJ) stent placement nine months prior presented with acute left scrotal swelling and fever. He had been lost to follow-up and managed voiding dysfunction with a chronically indwelling Foley catheter exchanged monthly at home. Examination revealed a tender, distended bladder and an erythematous, indurated left hemiscrotum with purulent drainage from the catheter. Laboratory investigations showed marked leukocytosis (WBC  $23 \times 10^3/\mu\text{L}$ ), and blood cultures grew *Klebsiella pneumoniae*. Scrotal ultrasound demonstrated a dense turbid fluid collection in the left hemiscrotum with the Foley catheter balloon visualized within the abscess cavity, confirming false passage. CT imaging revealed a markedly dilated left pelvicalyceal system with an in-situ DJ stent. The patient underwent urgent incision and drainage, revealing a  $6 \times 2$  cm urethro-scrotal fistula. Following sepsis control, a nephrectomy was performed, with histopathology confirming chronic pyelonephritis and end-stage renal disease. The scrotal wound healed completely.

**Conclusion:** This case represents a rare dual pathophysiology: a descending pyonephrotic infection creating vulnerable periurethral tissues, predisposing to iatrogenic urethro-scrotal fistula formation during routine catheter exchange. Clinicians should maintain a high index of suspicion for upper tract pathology in chronically catheterized patients presenting with scrotal infections, as definitive management requires addressing both the local complication and the remote infectious source.

**Keywords:** Scrotal abscess; Urethro-scrotal fistula; Pyonephrosis; Descending infection; Chronic Foley catheter; End-stage renal disease; Neglected ureteral stent.

## INTRODUCTION:

A scrotal abscess represents a urological and surgical emergency, often complicating conditions such as acute epididymo-orchitis or testicular torsion [1], [2]. Its development is associated with significant morbidity, including progression to overt sepsis or necrotizing fasciitis such as Fournier's gangrene, which carries a profound impact on patient morbidity and mortality [3], [4].

The etiology of scrotal infections is frequently linked to localized or ascending genitourinary tract infections. Chronic indwelling urinary catheter use is a well-established major risk factor, accounting for a substantial proportion of hospital-acquired infections by providing a direct conduit for bacterial colonization and ascent [5]. This risk is markedly exacerbated in patients with underlying comorbidities that compromise immune function or tissue integrity, such as diabetes mellitus (DM) and chronic kidney disease (CKD) [6]. In such populations, seemingly routine infections can rapidly progress to complex abscess formations.

In patients with CKD, inherent immune dysfunction increases susceptibility to bacterial colonization of the urinary tract [6]. When combined with the persistent foreign body of a chronic Foley catheter, this creates a perfect milieu for recurrent and severe catheter-associated urinary tract infections (CAUTIs) [5]. These infections can extend beyond the bladder via lymphatic drainage or direct tissue invasion, leading to severe complications in adjacent regions like the scrotum [6].

A urethro-scrotal fistula (USF) is an abnormal communication between the urethra and the scrotum, a rare but serious complication that can manifest as scrotal swelling or abscess [7], [8]. This pathology may be congenital or acquired, with acquired causes broadly categorized as iatrogenic (e.g., post-instrumentation or surgery), traumatic, or secondary to conditions such as urethral stones, infection, or neoplasia [8].

Traditionally, retrograde urethrography (RU) and voiding cystourethrography (VCU) have been the standard imaging modalities for diagnosing USF, as they can directly visualize the fistula tract and contrast extravasation [8]. However, these techniques are limited to evaluating the urethral lumen and provide little information on the surrounding periurethral tissues. Cross-sectional imaging, particularly multidetector computed tomography (MDCT) with reformatted images, has emerged as a valuable tool, offering comprehensive assessment of the fistula tract, associated abscess cavities, and adjacent anatomical structures [7].

While most scrotal pathologies arise from local or ascending sources, a descending route of infection from an upper urinary tract source to the perineum is exceedingly rare. A pertinent, though distinct, example is the formation of a perinephric abscess, which can itself fistulize to adjacent organs such as the colon, demonstrating the potential for severe, complicated infections to create abnormal communications across tissue planes [7]. This underscores that advanced upper tract disease can manifest remotely through fistula formation.

The intersection of chronic catheterization, tissue compromise, and infection creates a pathway for iatrogenic fistula formation. As illustrated in a case by Stizzo et al., a scrotal abscess in a diabetic male was drained via an iatrogenic urethro-scrotal fistula caused by improper catheterization [9].

However, the existing literature primarily describes fistulas arising from local trauma, stones, or as complications of perineal infections. The specific sequence of events where a descending infection from a chronic pyonephrotic kidney creates a vulnerable periurethral environment, subsequently leading to an iatrogenic urethro-scrotal fistula during routine catheter exchange, remains poorly documented. This report presents a novel case that elucidates this dual etiology a descending pyonephrotic infection weakening tissues, followed by catheter-induced perforation culminating in a scrotal abscess. We aim to highlight this unusual pathophysiology to aid in the timely recognition and comprehensive management of similar complex presentations.

### **Case Presentation:**

A 63-year-old Saudi male (DOB: 19 December 1960) presented to the emergency department on 25 December 2022 with a 3-day history of acute, painful left scrotal swelling and fever. His urological history was significant for left-sided pyelonephritis nine months prior (March 2022), for which he underwent cystoscopy and left retrograde pyelogram (RGP) with insertion of a 28-cm double-J (DJ) stent at an outside facility in Riyadh. Cystoscopy at that time had revealed an enlarged prostate, multiple bladder diverticuli with trabeculation and saccules, and a left ureteral orifice situated within a diverticulum. The RGP demonstrated a kinked ureter extending from the ureteropelvic junction (UPJ) to the ureterovesical junction (UVJ), and guidewire insertion was noted to be difficult. He was discharged with instructions for follow-up in 3 months but was subsequently lost to follow-up.

In the intervening period, the patient managed voiding dysfunction with a chronically indwelling Foley catheter (FC), exchanged monthly at home by a relative. He remained asymptomatic until this presentation.

On examination, the patient was vitally stable but febrile (temperature 38.4°C). Abdominal examination revealed a tender, palpable bladder with suprapubic tenderness. The Foley catheter was noted to be draining poorly, with purulent fluid visualized in the collection bag and was exchanged and about 700ml pyuria drained. Genital examination revealed a normal phallus, while the left hemiscrotum was markedly

swollen, erythematous, and indurated with a small area of black discoloration on the overlying skin, though no crepitus was appreciated. Both testes were palpably normal.

### Laboratory Investigations

On December 25, 2022, laboratory investigations revealed a white blood cell count of  $23 \times 10^3/\mu\text{L}$ , indicating marked leukocytosis, while hemoglobin levels remained within the normal range and C-reactive protein (CRP) was elevated.

Urine analysis indicated the presence of pus cells ( $>100$  per high-power field), and urine culture demonstrated mixed growth. Blood culture identified *Klebsiella pneumoniae*. Additionally, microbiological analysis on December 29, 2022, from a wound culture of the scrotal abscess revealed *Klebsiella pneumoniae* subspecies *pneumoniae*, classified as a multidrug-resistant organism (MDRO), and *Proteus mirabilis*, identified as moderately isolated (MI). Sensitivity testing indicated that *Klebsiella pneumoniae* exhibited resistance to multiple antibiotics, including ceftriaxone, ciprofloxacin, gentamicin, meropenem, piperacillin/tazobactam, and trimethoprim/sulfamethoxazole, while showing sensitivity to amikacin, ceftazidime, and tobramycin.

### Imaging findings

On December 25, 2022, from a scrotal ultrasound -Figure (1)- revealed both testes within the scrotal sac, normal in size and shape, with normal vascularity and unremarkable epididymis. However, the left scrotal compartment exhibited a dense turbid fluid collection. The urinary bladder was moderately distended with a thick, irregular wall and dense turbid fluid content displaying a fluid-fluid level, with a left DJ ureteric stent visualized and bilateral hydronephrosis noted and balloon of foley catheter within It scrotum ,this explained the false passage of the catheter. On March 5, 2023, a CT scan of the kidneys, ureters, and bladder showed the right kidney to be normal in size, shape, and position, with the pelvicalyceal system intact; however, it contained gravel in the lower calyx and no ureteric dilation. The left kidney was in a normal position but exhibited a markedly dilated pelvicalyceal system and contained no gross renal stones; a left ureteral stent was present. The urinary bladder appeared empty with a markedly thickened wall and was accompanied by a suprapubic catheter, with no stones detected.

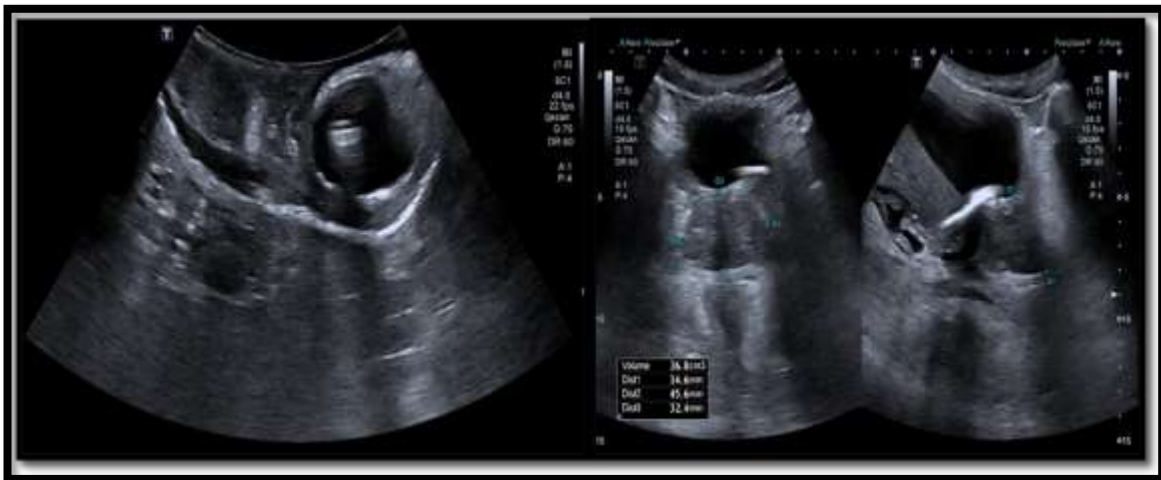

Figure 1:Imaging Findings from Scrotal Ultrasound(Ballon of foley catheter within left scrotum)

**Intervention and Findings:**

The Foley catheter was noted to be draining poorly, with purulent fluid visualized in the collection bag and was exchanged and about 700ml pyuria drained. The patient was started on broad-spectrum intravenous antibiotics and taken for urgent surgical exploration on 26 December 2022, Figure (2). Incision and drainage of the scrotal abscess was performed. Intraoperatively, a large urethro-scrotal fistula measuring approximately 6 cm in length and 2 cm in width was identified, creating a direct communication between the urethra and the left hemiscrotal cavity. This finding explained the false passage of the catheter observed on ultrasound. A suprapubic catheter (SPC) was inserted to divert urine away from the fistula and facilitate healing.

Following control of the acute septic episode, the underlying renal pathology was addressed. The patient subsequently underwent an uneventful left nephroureterectomy and removal of the indwelling DJ stent on 23 August 202

Histopathological analysis of the left kidney nephrectomy specimen on September 4, 2023, the diagnosis was chronic pyelonephritis with end-stage renal disease in the left kidney, and the specimen tested negative for malignancy.

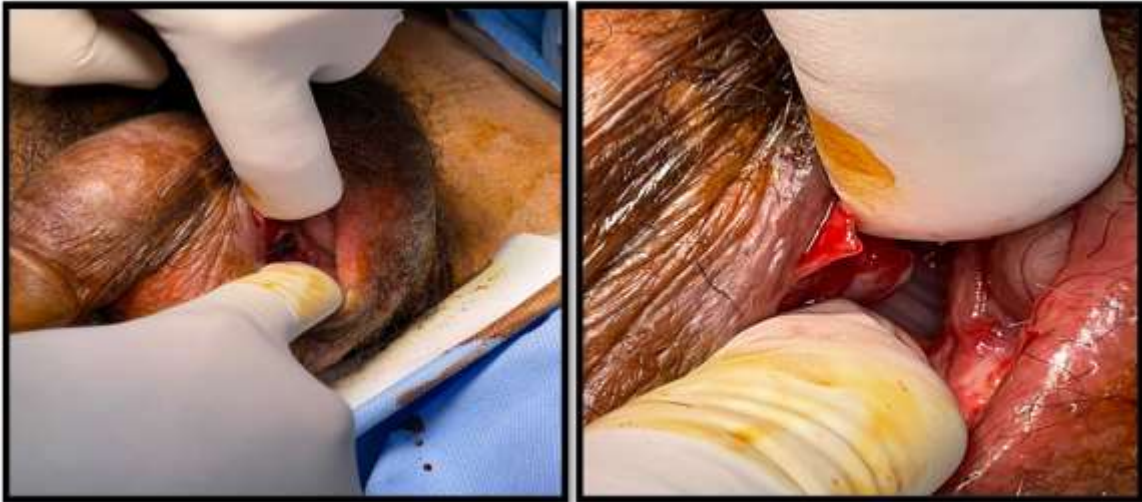

Figure 2: Surgical Exploration Findings and Urethro-Scrotal Fistula

**Outcome and Follow-up:**

The patient's clinical condition resolved completely following nephrectomy, with normalization of inflammatory markers and resolution of fever. An outpatient ascending urethrogram confirmed the presence of a urethral stricture proximal to the now-healed fistula site. The patient remains well with a suprapubic catheter in situ and is addressed for stricture management on follow-up visits, Figure (3,4).

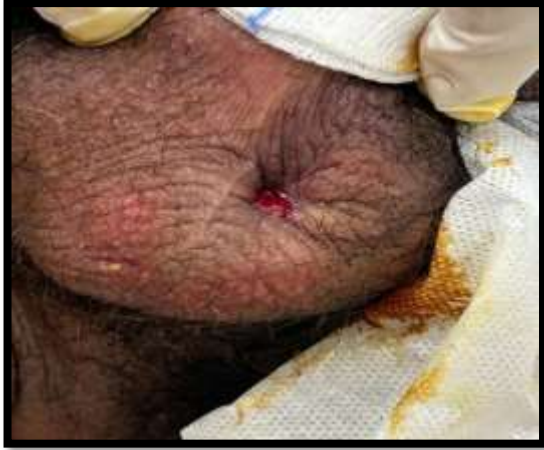

Figure 4: healing of scrotal fistula

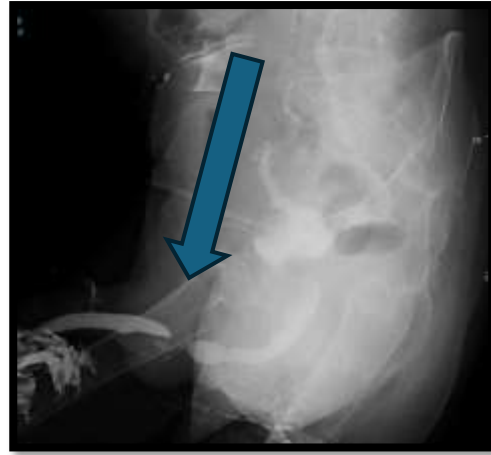


Figure 3: Ascending Urethrogram Findings Showing Urethral Stricture

### Discussion

The development of a scrotal abscess in a chronically catheterized patient typically implicates an ascending infection, where the indwelling Foley catheter provides a direct conduit for bacterial colonization of the urinary tract and subsequent extension to perineal tissues [5]. In our case, while ascending infection was undoubtedly a contributing factor given the positive cultures for *Klebsiella pneumoniae* and *Proteus mirabilis*, the primary underlying pathology was a descending process originating from a chronically infected, non-functioning left kidney. This distinction is critical, as the definitive resolution of the scrotal abscess was only achieved following nephrectomy, underscoring that the pyonephrotic kidney served as the persistent source of sepsis.

The presence of a neglected ureteral stent, placed nine months prior for pyelonephritis, likely contributed to the progressive deterioration of renal function and chronic bacterial colonization. As noted in the literature, underlying disease comorbidities such as CKD, prior instrumentation, and urinary obstruction decrease host immunity and enhance susceptibility to severe, complicated infections [6]. Our patient's histopathological diagnosis of chronic pyelonephritis with end-stage renal disease confirms that the kidney had become a non-functional reservoir of infection. This created a state of chronic inflammation that likely weakened surrounding tissue planes, including the periurethral tissues, making them susceptible to injury.

The iatrogenic component of this case the formation of a urethro-scrotal fistula during routine Foley catheter exchange illustrates the dangerous intersection of compromised host tissues and routine medical care. Similar to the case described by Stizzo et al., where improper catheterization in a diabetic patient led to fistula formation and abscess drainage [9], our patient's tissues were predisposed to perforation by the underlying chronic inflammation from the descending pyonephrotic infection. The scrotal ultrasound finding of the Foley balloon within the scrotal abscess cavity was pathognomonic for this false passage, and the intraoperative finding of a 6 × 2 cm fistula confirmed the extent of the injury.

The microbiological profile of our case, with isolation of multidrug-resistant *Klebsiella pneumoniae*, reflects the growing challenge of managing infections in patients with chronic indwelling devices and recurrent antibiotic exposure [5], [6]. Sensitivity testing guided the selection of appropriate antimicrobial therapy, with amikacin, ceftazidime, and tobramycin demonstrating efficacy. As emphasized in previous reports, tailoring antibiotics to local susceptibility patterns and patient-specific factors such as renal function is essential for optimizing outcomes and preventing further complications like Fournier's gangrene [3], [10]. The surgical approach, involving both scrotal drainage and eventual source control via nephrectomy, was the cornerstone of successful management in this complex case.

### Conclusion

Chronic Foley catheter use is a well-established risk factor for ascending genitourinary infections and scrotal abscess formation. However, this case highlights an unusual and important variant: a descending infection from a pyonephrotic, non-functioning kidney that created a vulnerable periurethral environment, predisposing the patient to iatrogenic urethro-scrotal fistula formation during routine catheter exchange. The presence of a neglected ureteral stent and underlying end-stage renal disease further compounded the infectious burden. Timely surgical intervention with scrotal drainage and suprapubic catheter diversion, followed by definitive source control via nephrectomy and stent removal, was essential for achieving complete resolution. This case underscores the necessity for a high index of suspicion for upper tract pathology in patients with complex urological histories and scrotal infections and reinforces the importance of multidisciplinary management and adherence to catheter care protocols to prevent such severe complications.

### Reference List:

- [1] D. Moher, A. Liberati, J. Tetzlaff, and D. G. Altman, "What is beyond testicular torsion and epididymitis? Rare differential diagnoses of acute scrotal pain in adults: A systematic review," *Annals of Medicine and Surgery*, vol. 55, no. 5, pp. 265–274, Jul. 2020, doi: 10.1016/j.ijvsu.2010.02.007.
- [2] M. M. Saleem, "Scrotal abscess as a complication of perforated appendicitis: A case report and review of the literature," *Cases Journal* 2008 1:1, vol. 1, no. 1, pp. 165-, Sep. 2008, doi: 10.1186/1757-1626-1-165.
- [3] N. Eke, "Fournier's gangrene: a review of 1726 cases," *Br. J. Surg.*, vol. 87, no. 6, pp. 718–728, 2000, doi: 10.1046/j.1365-2168.2000.01497.x.
- [4] C. E. Ogbu, K. Le, S. C. Ogbu, T. Ingram, and B. Ingram, "Scrotal Abscess in a Patient With Chronic Kidney Disease and a Chronic Foley Catheter: A Case Report," 2025, doi: 10.7759/cureus.78677.
- [5] S. Saint, "Clinical and economic consequences of nosocomial catheter-related bacteriuria," *Am. J. Infect. Control*, vol. 28, no. 1, pp. 68–75, 2000, doi: 10.1016/S0196-6553(00)90015-4.
- [6] S. B. Naqvi and A. J. Collins, "Infectious complications in chronic kidney disease," *Adv. Chronic Kidney Dis.*, vol. 13, no. 3, pp. 199–204, Jul. 2006, doi: 10.1053/j.ackd.2006.04.004.
- [7] T. J. S. Durant, J. Olsen, V. K. Bhuvra, J. Mogen, and J. Jacob, "Perinephric Abscess with Fistula Formation to Descending Colon: A Case Report and a Review of the Literature.," *Conn. Med.*, 2015.
- [8] S. Parlak and A. E. Okay, "Urethroscrotal Fistula: A Rare Cause of Scrotal Swelling," *Pol. J. Radiol.*, vol. 81, p. 438, Sep. 2016, doi: 10.12659/PJR.897937.
- [9] M. Stizzo et al., "Scrotal Abscess Drained by Iatrogenic Urethral Fistula in an Adult Diabetic Male," *Case Rep. Urol.*, vol. 2017, no. 1, p. 9820245, Jan. 2017, doi: 10.1155/2017/9820245.