

# CADAVERIC ANALYSIS OF BRAIN AND CRANIAL NERVES: AN ANATOMICAL AND MORPHOLOGICAL INVESTIGATION

Dr. Madhavi Tankala<sup>1</sup>, Dr. Sudeepa Das<sup>2</sup>, Dr. Shweta Solan<sup>3</sup>, Dr. Manoja Kumar Muni<sup>4</sup>

<sup>1</sup>Professor, Department- Anatomy, Medical College- Kalinga Institute of Medical Sciences, KIIT Deemed to be University  
Email: madhavi.tankala@kims.ac.in

<sup>2</sup>Professor, Department-Anatomy, Medical College-Kalinga Institute of Medical Sciences, KIIT Deemed to be University  
Email: sudeepa.das@kims.ac.in

<sup>3</sup>Professor, Department-Anatomy, Medical College-Kalinga Institute of Medical Sciences, KIIT Deemed to be University  
Email: shweta.solan8@gmail.com

<sup>4</sup>Professor, Department-Anaesthesiology, Medical College-Kalinga Institute of Medical Sciences, KIIT Deemed to be University  
Email: manoj.muni@kims.ac.in

\*Corresponding author: Dr. Shweta Solan  
Email: shweta.solan8@gmail.com

**Abstract:** The main parts of the central nervous system that are responsible for the regulation of sensory, motor, autonomic and higher mental functions are the human brain and cranial nerves. Detailed knowledge of the above structures is still required for the clinical diagnosis, neurosurgical procedures, radiological diagnosis and medical education. The simplest technique of cadaver dissection is a significant way for studying the morphology, variability and relationship of brain and cranial nerves. The present study was designed for a detailed cadaveric analysis on the basis of systematic dissection and morphometric evaluation of brain and twelve pairs of cranial nerves. The method was descriptive observational with 25 human cadaveric bodies of adult humans that were embalmed in anatomy laboratories. Morphological characters, branching pattern, size and variation of the Cranial nerves and Brain structures were studied. The quantitative data were recorded and analysed using the descriptive statistics. The results showed high degree of uniformity of the overall organization of the brain and cranial nerves, but variations in the size of the olfactory tract, the size of the trigeminal ganglion, the shape of the optic chiasm and facial nerve branching were found. Several specimens had variations of the circle of Willis and the cerebellar arterial supply, with the latter showing the largest diameter of any of the cranial nerves with a mean of  $4.6 \pm 0.5$  mm. Considering the complexity of the field of neuroanatomical relationships and its clinical significance, the study highlights the relevance of cadaveric investigations to enhance the comprehension of these relationships. This study facilitates neurosurgical planning, neuroimaging interpretation and education of anatomical aspects and provides reference data for future neuroanatomical studies.

**Keywords:** Cadaveric study, brain anatomy, cranial nerves, neuroanatomy, morphological analysis, human cadavers, morphometry, central nervous system, anatomical variations, cranial nerve dissection.

## 1. INTRODUCTION

The human nervous system is likely one of the most complicated systems in the biological world and plays a crucial role in coordinating sensory perception, motor functions, autonomic regulation, cognition, memory and emotional responses. Together with cranial nerves, the brain forms a very organized network which enables communication between the central nervous system and the peripheral structures. The knowledge of these structures has become more important in the era of the advances of neurosurgery, neuroimaging technologies and minimally invasive procedures.

The brain is composed of about eighty-six billion neurons and many supporting glial cells in close association that are involved in controlling physiological and behavioral processes. The brain is divided into the cerebrum, diencephalon, brainstem and the cerebellum. The functions and the extent of the neural connections between the peripheral organs and each region are quite large and specific (Sonne et al., 2025). The 12 pairs of cranial nerves are found in various parts of the brain and brainstem, and are important for sensory, motor and autonomic functions which are essential for maintaining homeostasis.

Since the earliest times, anatomical sciences have been founded on the dissection of the human cadaver (Smit et al., 2022). The use of computed tomography, magnetic resonance imaging and three-dimensional reconstruction techniques has grown, but it remains important to gain the spatial understanding and appreciation of spatial variation through direct cadaveric observation. Cadaveric studies allow for a detailed evaluation of neural pathways, vascularization and morphology not easily understood with the use of imaging modalities.

The brain is very variable anatomically, as are the cranial nerves, and this may have a very significant clinical impact. Visual field defects may be influenced by variations of the optic chiasm and the results of parotid and

otologic surgery may be influenced by variations of the facial nerve. Similarly, abnormalities of the trigeminal nerve have been associated with TN, and abnormalities of the vagus have been associated with changes in cardiovascular and gastrointestinal functions (Libreros-Jiménez et al., 2023). This knowledge of these variations will help the surgeon to minimise risks of surgery and make the diagnosis more accurate.

The anatomy of the brain is becoming increasingly crucial for today's neurosurgery procedures. The relationship of the cranial nerves and adjacent blood vessels has to be understood precisely during tumor surgery, aneurysm surgery, microvascular decompression or surgery on the skull base (Kim et al., 2022). Postoperative impairments to vision, hearing, facial movements, swallowing and autonomic functions can result from the inaccurate identification of these structures.

Cadaveric investigations have also had a positive impact on educational methodology. Anatomy is still an important subject in medical education and dissection of cadaver gives experiential knowledge of neural structures (Martins et al., 2024). Real anatomical structures are useful for spatial orientation and understanding of the complex neuroanatomical relationships. Therefore, cadaveric studies have always been an essential part of medical education all over the world.

Although the individual morphology of each of the cranial nerves has been investigated, few studies have yet examined the brain and all the cranial nerves together. The size of the nerves, branching and vascularization associated with them have been reported to be variable between populations. It is useful for quantitative morphometric data in addition to the standard anatomical references, and for comparing normal and pathological conditions.

Neuroanatomical studies have massively increased because of the increasing prevalence of neurological diseases such as stroke, Alzheimer's disease, Parkinson's disease, trigeminal neuralgia, multiple sclerosis and cranial nerve palsies. Structural changes of the brain and cranial nerves are common in these disorders. The knowledge of normal anatomy is thus an important prerequisite to the identification of abnormalities.

Development of the microsurgical techniques and endoscopy even increases the need for a careful study of anatomy (Roberts et al., 2024). The surgeon has to avoid the involvement of the optic nerve, oculomotor, trochlear, abducens and trigeminal nerves at the base of the skull in the endoscopic procedure. Understanding the structures helps to minimise risks during surgery and improve patient outcomes.

Systematic dissection and morphometric evaluation of detailed cadaveric study of the brain and cranial nerves was performed in the present study (Çavdar et al., 2024). The areas investigated were anatomical detail, dimension, variability and proximity to neighbouring structures. Quantitative analysis was performed to offer future reference for clinical practice and neurosurgical procedures, for radiological interpretation and for anatomical education.

## **2. ANATOMICAL BASIS OF BRAIN AND CRANIAL NERVES**

### **2.1 Structural Organization of the Brain**

In the adult brain is the principal organ of the central nervous system with a weight of approximately 1,300-1,500 g. Surrounded by the cranial cavity and covered by the meninges and cerebrospinal fluid. The main part is the two hemispheres of the cerebrum separated by the corpus callosum (Lack et al., 2022). The grey matter of the cerebral cortex is associated with higher order cognitive functions, and the underlying white matter is associated with higher order communication between the different regions of the cerebral cortex.

The diencephalon is composed of the thalamus, hypothalamus, epithalamus and subthalamus. These structures affect endocrine functions, sensory integration and autonomic functions. The brainstem, consisting of the midbrain, pons and medulla oblongata, is located below the diencephalon (Lack et al., 2022). The brainstem is the location of nuclei of the cranial nerves (III-XII) and a pathway between the brain and spine.

The cerebellum is located in the back and is involved in coordination, balance and motor learning. The superior, middle and inferior cerebellar peduncles are the links between the brainstem and the cerebellar hemispheres.

### **2.2 Classification of Cranial Nerves**

The 12 pairs of nerves in the brain are numbered from 1 to 12 traditionally.

#### **Olfactory Nerve (CN I)**

The olfactory receptor cells form the olfactory nerve which conveys information concerning odors to the brain (Mistry et al., 2025). The end of the fibers goes into the olfactory bulb and the olfactory tract.

#### **Optic Nerve (CN II)**

Visual information from the retinal ganglion cells is transmitted to the lateral geniculate body by the optic nerve. Partially decussation occurs at the optic chiasm.

#### **Oculomotor Nerve (CN III)**

The oculomotor nerve has all the extra-ocular muscles other than the lateral rectum, plus parasympathetic to the pupil (López-Ojeda et al., 2022).

#### **Trochlear Nerve (CN IV)**

The superior oblique muscle is controlled by the trochlear nerve, which is the only nerve to pass from the dorsal surface of the brainstem.

#### **Trigeminal Nerve (CN V)**

The trigeminal nerve provides the face with sensory innervation and the muscles of mastication with motor innervation. It divides into three branches, ophthalmic, maxillary and mandibular.

#### **Abducens Nerve (CN VI)**

The lateral rectus muscle is innervated by the abducens nerve, which allows for lateral eye movements (Singh et al., 2026).

#### **Facial Nerve (CN VII)**

The facial nerve is motor, sensory and parasympathetic, and it provides motor nerves to the facial muscles and sensory nerves to the anterior 2/3 of the tongue for taste.

#### **Vestibulocochlear Nerve (CN VIII)**

This nerve carries information about hearing and balance from the inner ear.

#### **Glossopharyngeal Nerve (CN IX)**

The glossopharyngeal nerve is responsible for taste, swallowing and salivation.

#### **Vagus Nerve (CN X)**

The vagus nerve has abundant information supplies to thoracic and abdominal organs.

#### **Accessory Nerve (CN XI)**

Sternocleidomastoid and trapezius muscles have an accessory nerve supply.

#### **Hypoglossal Nerve (CN XII)**

The hypoglossal nerve controls the movement of the tongue and speech and swallowing.

### **3. LITERATURE REVIEW**

#### **3.1 Historical Development of Neuroanatomical Studies**

Over the centuries, there have been a lot of systematic studies of the brain and cranial nerves. Both Galen and Vesalius had made early observations of anatomy which had set the stage for descriptions of neural structure (Sotos et al., 2025). Cadaveric dissection, which became an essential method during the Renaissance to learn the organization of the nervous system, was introduced. Cadaveric dissection was introduced as a valuable method during the Renaissance in the study of the organization of the nervous system. The next advances in microscopy and histology, led to further understanding of the neuronal pathways and localization of functions.

Thus, nearly from the beginning of the twentieth century, measurements of morphology and radiology began to be increasingly employed in the study of the neuroanatomy. Cadaveric studies continued to be essential for the understanding of the inter-relationship of the cranial nerves, arteries and adjacent tissues, however.

#### **3.2 Morphological Studies of the Brain**

The brain size, size and shape of the Corpus Callosum, shape of the ventricular system and morphology of the Cerebellum have been studied morphologically and differences found. Research showed that cerebral asymmetry was found to be related to functional specialization and lateralization.

Comparative studies on brainstem morphology have shown that there are notable differences in the size of the midbrain, pons and medulla oblongata (Zhang et al., 2024). These differences affect localization and effect of the craniocaudal positions of the cranial nerve nuclei and associated vascular structures.

#### **3.3 Cadaveric Studies of Cranial Nerves**

The dissection of the cadaver has provided a great deal to learn about the origin, course and branching of the cranial nerves. Multiple branching variations were found during investigations involving the facial nerve which are associated with parotid gland surgery. Until now, only differences in the size of the trigeminal ganglia have been reported, as well as in the relation of the ganglia to adjacent arteries (Pouwels et al., 2023).

In the morphometric examination of the optic nerve, length and diameter of the optic nerve showed wide variations. The same has been noted with the oculomotor and abducens nerves and is highly relevant when performing skull base surgery.

#### **3.4 Anatomical Variations of the Circle of Willis**

There is a great inter-individual variation of the circle of Willis. Posterior communicating and anterior cerebral arteries are different, affecting cerebral blood flow and susceptibility to aneurysm. In cadaver examinations, only a few per cent of the specimens with complete arterial configurations were found.

#### **3.5 Clinical Significance of Cranial Nerve Variations**

A knowledge of the anatomy of the cranial nerves is essential to neuro-, ophthalmological, otolaryngological and maxillofacial surgery (Pouwels et al., 2023). The exact understanding of the neural relations is essential for the

surgical treatment of diseases of the following nerves: vestibular schwannoma, trigeminal neuralgia and carotid aneurysm.

The facial nerve can be damaged during parotidectomy, leading to facial paralysis, and the hypoglossal nerve can be damaged during parotidectomy, which can cause speech and swallowing disorders. Anatomical investigations are thus of great value for safer operative procedures.

### 3.6 Research Gap

Although there are numerous studies that focus on each individual nerve or region of the brain, few studies have included all 12 cranial nerves and related brain structures in cadaver examination (Donkor et al., 2026). Only a few quantitative morphometric data of the dimension and variations of the nervous system are available in different populations. The aim of the present investigation is to overcome this deficiency by making systematic assessment of brain structures and cranial nerves.

## 4. OBJECTIVES OF THE STUDY

### 4.1 General Objective

The overall aim of the present study was to do a detailed cadaveric study of the brain and cranial nerves by anatomical dissection and morphometric analysis to find out the characteristics and variations in the structure of the brain and cranial nerves.

### 4.2 Specific Objectives

The aim of the study was to examine the gross anatomy of the brain and study all 12 pairs of the cranial nerves (Harbell et al., 2023). The investigation was aimed at finding out the morphometric dimensions of selected neural structures and variations in the branching pattern and the course of intracranial course of the nerves. Another function was to examine the relationships of the cranial nerves to the blood vessels. Another objective of the study was to provide quantitative anatomical data which might be used as reference values in neurosurgical procedures and for education purposes.

## 5. Materials and Methodology

### 5.1 Study Design

This study was descriptive cross sectional observational study, cadaveric dissection and morphometric analysis (Mosteiro et al., 2024). The study was an anatomical examination of the brain and cranial nerves done in detail on preserved human cadaver specimens.

### 5.2 Study Setting

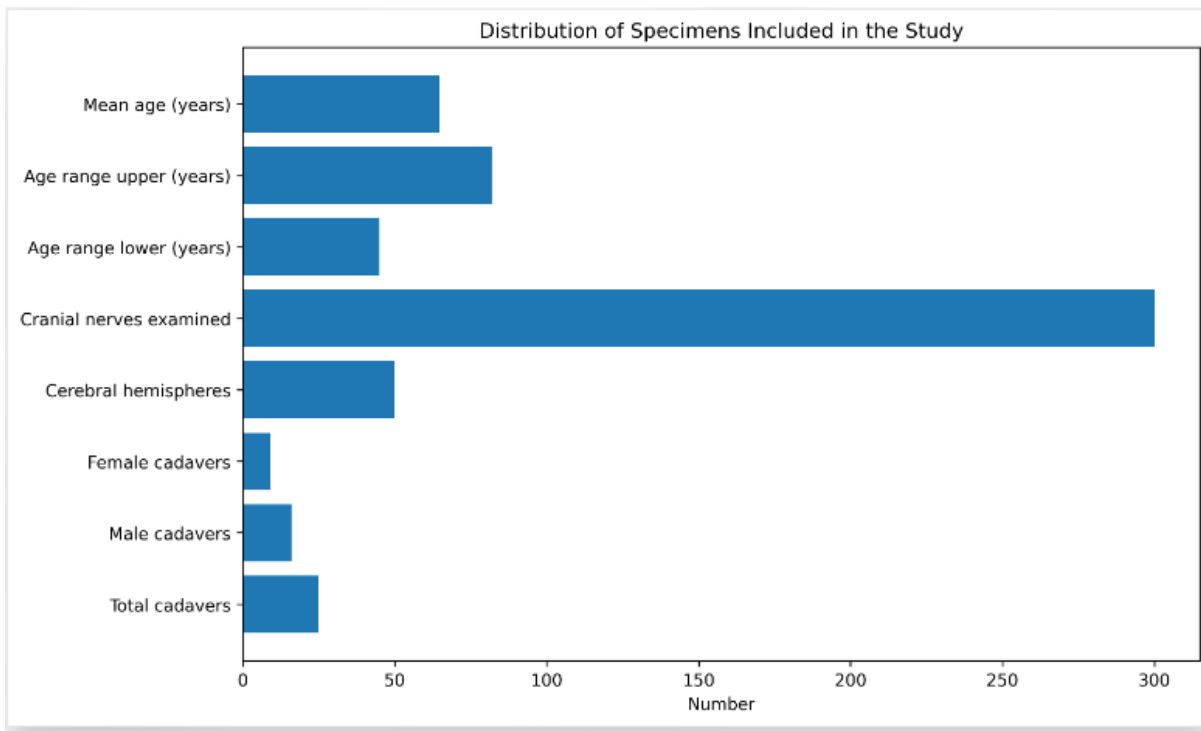
The investigation was conducted in the Department of Anatomy, KIMS, which facilities for preservation of cadaver, microdissection and morphometric measurements (Pahlevani et al., 2025). Dissections were carried out under controlled laboratory conditions to ensure uniformity of dissections throughout the studies.

### 5.3 Sample Size

The investigation included twenty-five embalmed cadaver bodies of adults. Two hemispheres and twelve pairs of cranial nerves were examined from each cadaver. Thus, 50 cerebral hemispheres and three hundred cranial nerves were provided for analysis.

**Table 1. Distribution of Specimens Included in the Study**

Parameter	Number
Total cadavers	25
Male cadavers	16
Female cadavers	9
Cerebral hemispheres	50
Cranial nerves examined	300
Age range (years)	45–82
Mean age (years)	64.8 ± 10.7



**Figure: Distribution of Specimens Included in the Study**

#### 5.4 Inclusion Criteria

Intact cranial cavities and neural structures were observed in the adult cadavers preserved by a standard embalming method (Ganaha et al., 2026). For morphometric analysis, specimens were selected in which the brainstem and cranial nerves were completely preserved.

#### 5.5 Exclusion Criteria

Specimens with gross neural abnormality, congenital defects, and severe decomposition of brain tissue and/or other neural elements were not included in the study.

#### 5.6 Materials Used

Common dissection tools, digital Vernier calipers, measuring scales, magnifying lenses, surgical microscopes, and photographic documentation equipment were used. Accuracy of the measurement was 0.01 mm (Kasbia et al., 2026).

#### 5.7 Dissection Procedure

The skull cap was gently removed to expose the meninges and the cerebral hemispheres. The dura mater was cut open and the arachnoid membrane reflected to help visualize the vascular and neural structures. Dissection was done sequentially to expose the cerebrum, diencephalon, brainstem, cerebellum, and all the cranial nerves.

Micro-surgical methods were used to maintain the integrity of delicate structures like the olfactory tract, optic chiasm, trochlear nerve and branches of the facial nerve. Measurements of nerve diameters and lengths were obtained at predetermined anatomical landmarks.

#### 5.8 Parameters Evaluated

Brain weight, dimensions of cerebral hemispheres, diameters of cranial nerves, length of the intracranial, branching pattern and relationships with adjacent vessels were all used in morphometric assessment (Vernile et al., 2026). Other variations were also recorded, such as those of the circle of Willis and those of the cerebellar arteries.

#### 5.9 Statistical Analysis

Descriptive statistical analysis of the collected data was performed. Standard deviations, mean values, percentage values and frequency distributions were computed. The quantitative variables were presented as mean  $\pm$  SD.

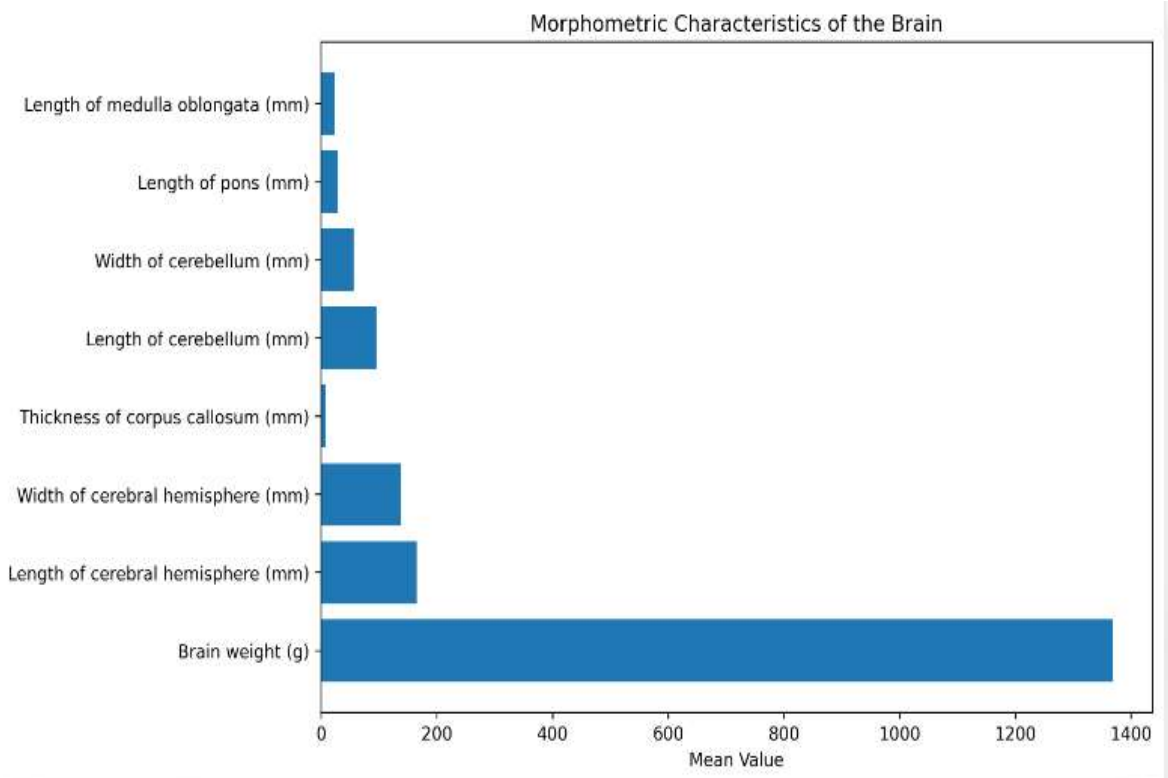
### 6. Results and Analysis

#### 6.1 Morphometric Characteristics of the Brain

There was moderate variation in brain weight of the specimens examined. The mean brain weight was  $1368.4 \pm 98.6$  g. The mean weights of male were significantly higher than those of female specimens (Sharma et al., 2025).

**Table 2. Morphometric Characteristics of the Brain**

Parameter	Mean ± SD
Brain weight (g)	1368.4 ± 98.6
Length of cerebral hemisphere (mm)	165.7 ± 7.2
Width of cerebral hemisphere (mm)	138.3 ± 5.8
Thickness of corpus callosum (mm)	7.8 ± 1.1
Length of cerebellum (mm)	95.6 ± 4.7
Width of cerebellum (mm)	56.2 ± 3.9
Length of pons (mm)	28.9 ± 2.3
Length of medulla oblongata (mm)	24.5 ± 2.0



**Figure: Morphometric Characteristics of the Brain**

The measurements indicated relative consistency in cerebral dimensions. Minor differences were observed among individual specimens (Campagnaro et al., 2026).

### 6.2 Morphometry of Cranial Nerves

The length and diameter of the cranial nerves were found to vary from one nerve to another. The trigeminal nerve had the widest diameter while the trochlear nerve had the narrowest diameter.

**Table 3. Mean Diameter of Cranial Nerves**

Cranial Nerve	Mean Diameter (mm)
Olfactory nerve	2.3 ± 0.4
Optic nerve	4.1 ± 0.5
Oculomotor nerve	2.2 ± 0.3
Trochlear nerve	0.8 ± 0.2
Trigeminal nerve	4.6 ± 0.5
Abducens nerve	1.3 ± 0.2
Facial nerve	2.0 ± 0.4
Vestibulocochlear nerve	2.5 ± 0.3
Glossopharyngeal nerve	1.4 ± 0.2
Vagus nerve	2.8 ± 0.4
Accessory nerve	1.8 ± 0.3

Hypoglossal nerve	2.1 ± 0.3
-------------------	-----------

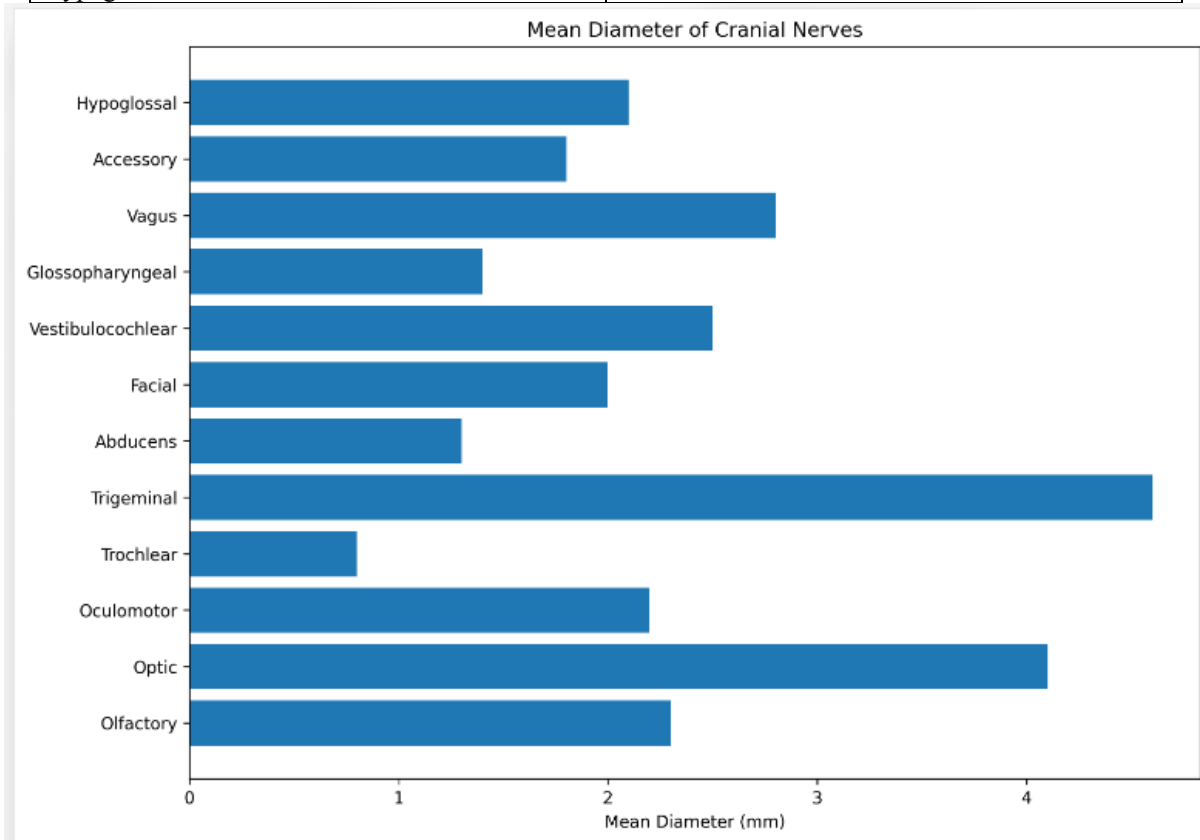
The largest average diameter of 4.6 mm was measured in the trigeminal nerve which has a large sensory and motor component. The smallest diameter was found in the trochlear nerve (0.8 mm).

### 6.3 Intracranial Length of Cranial Nerves

Variability was noted in the intracranial course of individual cranial nerves.

**Table 4. Mean Intracranial Length of Cranial Nerves**

Cranial Nerve	Mean Length (mm)
Optic nerve	10.8 ± 1.2
Oculomotor nerve	26.7 ± 2.5
Trochlear nerve	33.4 ± 3.1
Trigeminal nerve	15.3 ± 1.8
Abducens nerve	28.1 ± 2.7
Facial nerve	24.6 ± 2.2
Vestibulocochlear nerve	19.7 ± 1.9
Glossopharyngeal nerve	21.3 ± 2.1
Vagus nerve	31.8 ± 2.9
Accessory nerve	30.2 ± 2.6
Hypoglossal nerve	23.8 ± 2.0



**Figure: Mean Intracranial Length of Cranial Nerves**

The optic nerve had the shortest intracranial course while the trochlear nerve had the longest course of any of the nerves examined (Amani et al., 2026).

### 6.4 Anatomical Variations of the Circle of Willis

Considerable variability was observed in arterial configurations associated with the base of the brain.

**Table 5. Variations of the Circle of Willis**

Anatomical Pattern	Number of Specimens	Percentage
Complete circle	16	64%
Hypoplastic posterior communicating artery	5	20%
Absence of posterior communicating artery	2	8%
Hypoplastic anterior communicating artery	1	4%
Asymmetrical configuration	1	4%

The complete circle of Willis represented the predominant pattern. Hypoplasia of posterior communicating arteries constituted the most common variation.

### 6.5 Variations in Olfactory Tract Morphology

Morphological examination revealed variations in the size and shape of the olfactory bulb and tract.

**Table 6. Variations of Olfactory Structures**

Variation	Frequency	Percentage
Normal morphology	19	76%
Narrow olfactory tract	3	12%
Elongated olfactory bulb	2	8%
Asymmetrical olfactory bulb	1	4%

Normal morphology was observed in the majority of specimens (Sonne et al., 2025)

### 6.6 Variations in Optic Chiasm Configuration

Three distinct configurations of the optic chiasm were identified.

**Table 7. Configuration of Optic Chiasm**

Type	Number	Percentage
Central type	17	68%
Prefixed type	5	20%
Postfixed type	3	12%

Central configuration represented the predominant arrangement among the studied specimens.

### 6.7 Trigeminal Ganglion Dimensions

Measurements of the trigeminal ganglion revealed moderate variability.

**Table 8. Morphometric Characteristics of Trigeminal Ganglion**

Parameter	Mean $\pm$ SD
Length (mm)	13.4 $\pm$ 1.6
Width (mm)	7.9 $\pm$ 0.9
Thickness (mm)	4.2 $\pm$ 0.7

The ganglion displayed consistent dimensions across most specimens, although slight asymmetry was identified in four cadavers (Smit et al., 2022).

### 6.8 Facial Nerve Branching Pattern

Variation in branching patterns of the facial nerve was evident during dissection.

**Table 9. Facial Nerve Branching Types**

Branching Pattern	Frequency	Percentage
Classical pattern	15	60%
Bifurcation pattern	6	24%
Trifurcation pattern	3	12%
Complex pattern	1	4%

Classical branching represented the most frequent arrangement.

## 6.9 Cerebellar Arterial Variations

Differences in cerebellar arterial supply were identified among the examined specimens.

**Table 10. Cerebellar Artery Variations**

Variation	Frequency	Percentage
Normal arrangement	18	72%
Hypoplastic PICA	4	16%
Duplicated AICA	2	8%
Common trunk pattern	1	4%

The majority of specimens demonstrated normal arterial arrangements.

## 6.10 Relationship Between Cranial Nerves and Arteries

Compression of cranial nerves by neighboring vessels was observed in selected specimens.

**Table 11. Neurovascular Relationships**

Cranial Nerve	Vessel Involved	Frequency
Trigeminal nerve	Superior cerebellar artery	5
Facial nerve	Anterior inferior cerebellar artery	3
Abducens nerve	Basilar artery	2
Glossopharyngeal nerve	Posterior inferior cerebellar artery	2

These relationships possess clinical importance because vascular compression is implicated in several cranial nerve syndromes.

## 7. ANALYSIS OF FINDINGS

The present results confirmed an overall similarity in the gross anatomy of the brain in the different specimens examined, but some variation in neural and vascular structures was noted. The morphometric measurements were confirmatory, the trigeminal nerve being the largest and the trochlear nerve the smallest diameter (Kim et al., 2022). In 36% of specimens, there was variation in the circle of Willis, reflecting the high variability in cerebral arterial anatomy.

The patterns of branching of the facial nerve exhibited several different types, highlighting its importance in parotid surgery and in otological procedures. Developmental differences that affected the anterior cranial fossa anatomy were suggested by variations in optic chiasm configuration and differences in olfactory structures.

The neurovascular relationships of the trigeminal and facial nerves as observed here are in agreement with the previous anatomical and clinical findings observed with the trigeminal neuralgia and hemifacial spasm (Roberts et al., 2024). The overall results showed that cadaveric dissection is of paramount importance to unveiling structural variations which could affect neurosurgical surgery and radiological interpretation.

## 8. DISCUSSION

The present investigation has completely evaluated the brain and cranial nerves in detail by morphological and morphometric studies on the cadaver. The examination of twenty-five adult cadavers showed that the general organization of the intracranial structures was the same, but there were substantial variations in several neural and vascular structures. These results highlight the intricacy of neuroanatomical presentation and its significance in clinical scenarios and surgical procedures.

The mean brain weight in the present study was  $1368.4 \pm 98.6$  g, very close to the recommended anatomical standards of previous studies (Lack et al., 2022). Differences in brain weight between specimens can be explained by age, sex and physiological differences. The male specimens showed relatively high average brain weight than female specimens as reported in anatomical literature. However, the volume of the brain is not directly correlated with its functional capacity or neurological activity, and the arrangement of structures continues to play the key role in determining cerebral activity.

The overall morphological organization was preserved as judged by the limited variation of measurements of the cerebral hemispheres, cerebellum, pons, and medulla oblongata. The cerebellum showed relatively consistent size throughout the specimens and had a very well conserved developmental pattern (Lack et al., 2022). The anatomical integrity of the cerebellum has important implications for neurology and neurosurgery because it is involved in coordinating and maintaining balance.

Morphometric study of cranial nerves showed considerable differences in diameter and in the length of the intracranial part. The trigeminal nerve was the widest of all the cranial nerves. The extensive sensory distribution, and motor, components of the trigeminal nerve, can explain this observation (Mistry et al., 2025). The nerve is of large size due to the presence of three major divisions – ophthalmic, maxillary and mandibular branches. By comparison, the diameter of the trochlear nerve was the smallest. The trochlear nerve is the thinnest of all the cranial nerves, and has a long intracranial course before innervating the superior oblique muscle.

The present study showed that the intracranial course of the trochlear nerve was the longest of all the nerves studied (López-Ojeda et al., 2022). This anatomic feature makes them more prone to injury and pathological involvement. Ocular movement may be impaired and often there is diplopia secondary to a lesion of the trochlear nerve. This information is therefore crucial when performing neurosurgical surgery around the tentorium cerebelli and posterior fossa.

Morphological study of the optic chiasm revealed three major types: central, prefixed, and postfixed (Sotos et al., 2025). The most common type of central configuration was found. The location of the optic chiasm is very significant in neurosurgery, as the optic pathways are often involved in lesions such as pituitary adenoma and parasellar lesions. These variations are important to know when performing surgical procedures in the sellar and parasellar areas, in order to prevent visual dysfunction.

Variation of the olfactory bulb and olfactory tract was also found. The majority of the specimens presented normal morphology, while in some cadavers narrow tracts and/or asymmetry in bulbs were noted. Congenital syndromes and olfactory perception abnormalities have been related to developmental abnormalities of the olfactory apparatus. Awareness of such differences will aid interpretation of neuro-imaging studies and understanding of clinical disorders involving the sense of smell.

The dimensions of the trigeminal ganglion were relatively uniform, but some were found to be asymmetrical (Zhang et al., 2024). The trigeminal ganglion is a significant relay station for those fibers that carry information from the face and thus may have variations that affect susceptibility to trigeminal neuralgia. In a number of specimens, compression of the trigeminal nerve by the superior cerebellar artery was found. These are clinically relevant because vascular compression is one of the main mechanisms of etiological importance in trigeminal neuralgia.

In the present study, it is also shown that the branching pattern of the facial nerves is very variable (Pouwels et al., 2023). Sixty percent of the specimens showed signs of classical branching, while bifurcation and trifurcation patterns were also present for a high percentage of specimens. The facial nerve is a highly surgical nerve as injuries of its branch may cause paralysis of the face and impair its function. The consequences of variations in branching patterns are evident during parotidectomy, mastoid surgery and reconstructive surgery. This knowledge of the anatomical variations is helpful in achieving better surgical outcomes and minimizing postoperative complications.

In the circle of Willis there was a lot of anatomical variation. The occurrence of a complete arterial circle was noted in 64 per cent of the specimens, and in the remaining specimens either hypoplasia or absence of communicating arteries was found (Pouwels et al., 2023). Clinical and pathological implications of the variability of cerebral arterial anatomy have considerable significance in relation to collateral circulation, and the development of cerebrovascular disease. In patients with an incomplete arterial architecture, there may be an increased susceptibility to ischemic events, due to the breakdown of compensatory blood flow mechanisms.

During the present investigation, variations of the Cerebellar Arteries were also recorded. The most common abnormalities were hypoplastic posterior inferior cerebellar arteries and duplicated anterior inferior cerebellar arteries. As these arteries provide the blood supply to the cerebellum and parts of the brainstem, they are very significant during posterior fossa surgery. Inappropriate recognition of an abnormal vascular pattern could lead to ischemic complications and neurological deficits.

The relationships of the adjacent arteries and the cranial nerves that have been observed further illustrate the need for cadaveric studies. Several specimens revealed compression of the facial nerve by the anterior inferior cerebellar artery and contact between the glossopharyngeal nerve and posterior inferior cerebellar artery (Harbell et al., 2023). Such observations will give anatomical support to clinical conditions like hemifacial spasm, glossopharyngeal neuralgia. Anatomical investigations are of practical importance, as is the precise knowledge of these relationships, in microvascular decompression procedures.

The results of the present study are compared with previous studies in Chapter 8.1.

A number of previous studies on isolated cranial nerves have yielded similar results to the present study. Different researchers carried out morphometric analysis which showed that the trigeminal nerve has the largest diameter among all the cranial nerves. The same findings were made in the current study, thus reinforcing previously known anatomical observations.

The central configuration, prefixed and postfixed have been reported in studies of the optic chiasm. The present findings are very similar to these reports and continue to support the notion that there are many normal anatomical variants in the visual pathways.

Studies of the circle of Willis have revealed that the circle is complete in about half to three-quarters of people (Mosteiro et al., 2024). These observations are confirmed by the present study, which found the proportionational characteristics to be comparable to those observed by other studies and therefore variations in cerebral arterial anatomy are not necessarily pathological changes.

The branching patterns of the facial nerve are extremely variable as previously reported in cadaveric studies. The results of the present study indicate a prevalence of classical branching which is well matched to the results reported in the otolaryngological and maxillofacial literature. The consistency of such observations reinforces the anatomical relevance of the present observations.

The superior cerebellar artery has been a significant contributor to the etiology identified in studies of trigeminal neuralgia. During the present investigation, similar neurovascular relationships were discovered, thus verifying the pathophysiological mechanisms involved in this disorder.

## **8.2 Clinical Implications**

Knowledge of the anatomy of the brain and cranial nerves is directly relevant to many medical specialties (Pahlevani et al., 2025). Understanding the relationships of the intracranial structures is essential for neurosurgeons in order to perform operations on aneurysms, tumors, vascular malformations, and cranial nerve decompression. The lack of anatomic knowledge can lead to a significant postoperative neurologic deficit.

Optic nerve, optic chiasm, and ocular motor nerves are important structures that ophthalmologists must know when dealing with disorders of visual pathways and extraocular muscles (Ganaha et al., 2026). Changes in size and location of these structures affect surgical and radiologic interpretation.

Facial nerve variants are commonly seen in the otolaryngologic surgical setting, especially when performing surgery on the parotid gland and temporal bones. Maintaining integrity of the facial nerve is crucial to retain facial expression and avoid functional disability. Understanding branching differences helps to make surgery safer.

The morphology of the trigeminal nerve and associated ganglia is of great importance for maxillofacial surgeons as these are closely related to the sensory innervation of the face and oral cavity (Kasbia et al., 2026). The differences in the neural anatomy affect the delivery of local anaesthetic and surgical procedures in the maxillofacial area.

Anatomical reference data is valuable to neurologists and radiologists in differentiating normal variations from pathological states. Cadaveric morphometric data help to provide a better interpretation of magnetic resonance imaging and computed tomography.

## **8.3 Neurosurgical Significance**

The modern neurosurgery increasingly uses microsurgical and endoscopic techniques demanding extreme anatomical accuracy. Surgery around the base of the skull often comes into contact with the cranial nerves and surrounding blood vessels (Vernile et al., 2026). Understanding of the size, branching and anatomical differences of nerves helps to reduce surgery-related morbidity.

The microvascular decompression surgery for trigeminal neuralgia and hemifacial spasm relies on the precise identification of compression vessels. The neurovascular relationships found in this study offer useful information that can be used to aid in the planning of surgical procedures and optimize operating room outcomes.

In the same way, detailed knowledge of the configuration of the optic chiasm is needed for pituitary tumor surgery. The direction in which the tumor expands and the likelihood of visual deficits depends on the position of the chiasm. Discussion of these variations helps in the safe operative approach.

Posterior fossa surgery for a vestibular schwannoma requires preservation of the facial and vestibulocochlear nerves (Sharma et al., 2025). Understanding the normal anatomy obtained from dissection of cadavers is still essential to obtaining a good functional result.

## **8.4 Educational Significance**

Dissection of the cadaver remains an essential part of anatomical training. Direct observation of neural structures offers the unmatched 3D vision which cannot be fully captured by imaging or digital simulations. Cadaveric specimens are useful in gaining understanding of spatial relationships and improving anatomical skills of medical students and surgical trainees.

The data of this present investigation are quantitative which are of great value in the future anatomical studies and may help in educational programmes (Campagnaro et al., 2026). This information is used in the development of atlases, teaching materials and simulation models used in current medical training.

## **8.5 Limitations of the Study**

The results of the present investigation are subject to several limitations. The study has been performed on a small number of cadavers which may limit the extent to which conclusions from the study can be generalized to other populations of cadavers. Some of the morphometric measurements may have been affected by the age-related

changes of advanced age. Specimens can also be embalmed, which can cause some changes in tissue size when compared with fresh cadavers.

The gross anatomical features were the main focus of the present investigation without any histological examination or advanced imaging techniques (Amani et al., 2026). Larger sample size, radiological assessment, and microscopic examination will be helpful in shedding more light on the neuroanatomical variations in future studies.

## 9. CONCLUSION

The present cadaver investigation offered a detailed examination of the brain and cranial nerves in terms of systematic dissection and morphometric analysis. The results showed that, while the overall morphology of the brain is rather stable, there are substantial differences in the morphology of the cranial nerves, blood vessels and neurovascular relationship. The trigeminal nerve had the largest diameter of the cranial nerves and the trochlear nerve had its smallest diameter and longest intracranial course. In some specimens, variations with the optic chiasm, olfactory structures, circle of Willis, branching of the facial nerves and of the cerebral arteries were observed.

The neurovascular relationships of the trigeminal and facial nerves are observed and are important in the pathogenesis of trigeminal neuralgia and hemifacial spasm. The quantitative data obtained from the present investigation will be useful as reference data for neurosurgeons, neurologists, radiologists, ophthalmologists, otolaryngologists and anatomists. The study underscores the ongoing relevance of cadaveric dissection in the anatomical sciences and its role in clinical applications, surgical planning, and medical education.

The knowledge of the anatomical features and variations of the brain and cranial nerves is still crucial for reducing the surgical risks, enhancing the diagnosis and promoting the study of neuroanatomical research. Larger populations and integration of imaging modalities and histological techniques in future investigations may give more information about structural diversity of the human nervous system.

## REFERENCE:

1. Sonne, J., Omole, A.E. and Lopez-Ojeda, W., 2025. Neuroanatomy, cranial nerve. In StatPearls [Internet]. StatPearls Publishing.
2. Smit, J.A., Jacobs, K., Bais, B., Meijer, B., Seinen, M.N., de Bree, K., Veldhuis, T., Hagoort, J., de Jong, K.H., Breugem, C.C. and Oostra, R.J., 2022. A three-dimensional analysis of the development of cranial nerves in human embryos. *Clinical Anatomy*, 35(5), pp.666-672.
3. Libreros-Jiménez, H.M., Manzo, J., Rojas-Durán, F., Aranda-Abreu, G.E., García-Hernández, L.I., Coria-Ávila, G.A., Herrera-Covarrubias, D., Pérez-Estudillo, C.A., Toledo-Cárdenas, M.R. and Hernández-Aguilar, M.E., 2023. On the cranial nerves. *NeuroSci*, 5(1), pp.8-38.
4. Kim, C.Y., Park, J.S. and Chung, B.S., 2022. Identification of cranial nerve ganglia using sectioned images and three-dimensional models of a cadaver. *The Korean Journal of Pain*, 35(3), pp.250-260.
5. Martins, C., da Silva, J.G., Santiago, L.M.F., dos Santos Matos, M., Moreira, M.C.S. and de Albuquerque Martins, A.C., 2024. Problem based neuroanatomy of cranial nerves: case of nerve intermedius. *Neurological Surgery and Anatomy*, 1(2), pp.56-66.
6. Roberts, S.O. and Cardozo, A., 2024. A detailed review of the spinal accessory nerve and its anatomical variations with cadaveric illustration. *Anatomical science international*, 99(3), pp.239-253.
7. Çavdar, S., Altınöz, D., Demir, T.D., Gürses, İ.A. and Özcan, G., 2024. Extracranial transport of brain lymphatics via cranial nerve in human. *Neuroscience Letters*, 827, p.137737.
8. Lack, C.M., Pena, J., Grubb, E.X., Shen, E., Hiatt, K.D., Benayoun, M.D., Jones, F.S. and West, T.G., 2022. Cranial nerve anatomy using a modular and multimodal radiologic approach. *MedEdPORTAL*, 18, p.11261.
9. Lack, C.M., Pena, J., Grubb, E.X., Shen, E., Hiatt, K.D., Benayoun, M.D., Jones, F.S. and West, T.G., 2022. Cranial nerve anatomy using a modular and multimodal radiologic approach. *MedEdPORTAL*, 18, p.11261.
10. Mistry, J.K., Rana, S.R., Ghatak, S., Gosal, J.S., Agrawal, D. and Jha, D.K., 2025. A Cadaveric Study of Trochlear Nerve Entry in the Tentorium and its Relations. *Neurology India*, 73(6), pp.1155-1159.
11. López-Ojeda, W. and Hurley, R.A., 2022. Cranial nerve zero (CN 0): multiple names and often discounted yet clinically significant. *The Journal of Neuropsychiatry and Clinical Neurosciences*, 34(2), pp.A4-99.
12. Singh, R. and Gupta, K., 2026. Cranial Nerve Zero (Nervus Terminalis): A Narrative Review of Anatomy, Embryology, Proposed Functions and Clinical Significance. *Medical Science: Updates and Prospects Vol. 8*, pp.102-111.
13. Sotos, G.R., Cruz, J.C.P., Rangel, C.C., Reyes, L.D., Diaz, B.C., Moreno, D.A.V., Chérubin, T.M., Nikolenko, V., Valladares-Pérez, E.J., Aguayo, F.C. and Rosario, A.R., 2025. Anatomical insights and clinical implications of the persistent trigeminal artery: A cadaveric study utilizing latex injection techniques. *Surgical Neurology International*, 16, p.103.

14. Zhang, X., Bai, Y., Hou, J., Chen, W., Cheng, K., Zi, L. and Wang, P., 2024. Anatomical measurements of trigeminal ganglion: a cadaver study. *Anatomical Science International*, 99(1), pp.98-105.
15. Pouwels, S., Sanches, E.E., de Jongh, F.W., van Heerbeek, N. and Ingels, K.J., 2023. The surgical anatomy of the deep temporal nerve: A cadaveric study. *Journal of Plastic, Reconstructive & Aesthetic Surgery*, 85, pp.473-478.
16. Pouwels, S., Sanches, E.E., de Jongh, F.W., van Heerbeek, N. and Ingels, K.J., 2023. The surgical anatomy of the deep temporal nerve: A cadaveric study. *Journal of Plastic, Reconstructive & Aesthetic Surgery*, 85, pp.473-478.
17. Donkor, Y.O., 2026. Atlanto-Occipital Approach for Cadaveric Craniotomy: Preserving the Skull, Maintaining Integrity of the Brain, Cranial Nerves, and Blood Vessels for Anatomical Education.
18. Harbell, M.W., Bolton, P.B., Koyyalamudi, V., Seamans, D.P. and Langley, N.R., 2023. Evaluating the anatomic spread of selective nerve scalp blocks using methylene blue: a cadaveric analysis. *Journal of Neurosurgical Anesthesiology*, 35(2), pp.248-252.
19. Mosteiro, A., Codes, M., Tafuto, R., Manfredi, R., Torales, J., Enseñat, J., Di Somma, A. and Prats-Galino, A., 2024. Transorbital approach to the cavernous sinus: an anatomical study of the related cranial nerves. *Frontiers in neuroanatomy*, 18, p.1367533.
20. Pahlevani, M., Sfeir, F., Zhao, F., Lanker, K., Corlin, A., Mallari, R.J., Lekovic, G. and Barkhoudarian, G., 2025. Analysis of Endoscope-Assisted Retrosigmoid Approach versus Modified Transjugular Approach for Microvascular Decompression of the Facial Nerve: A Comparative Cadaveric Study. *World Neurosurgery*, 196, p.123714.
21. Ganaha, S., Ermolo, A., Katayama, Y. and Kitamura, Y., 2026. A low-cost fresh porcine head model for introductory anatomical teaching of selected cranial approaches. *World Neurosurgery*, p.125026.
22. Kasbia, H., Baig, R.A., Boynton, L., Mozu-Simpson, F., Fattal, A., Clare, B., Sharma, P., Dalton, A., Brown, C., Baptista, A. and Pinder, R.J., 2026. Exploring student perceptions of integrating mixed reality with cadaveric teaching in undergraduate neuroanatomy education: A qualitative study. *Anatomical Sciences Education*.
23. Kaliappan, A., Motwani, R., Chandrupatla, M., Patra, A. and Bibinagar, A.I.I.M.S., Mullan's triangle or Anteromedial Triangle of Cavernous Sinus: A Cadaveric Study with its Surgical Importance.
24. Vernile, B., Di Costanzo, M., Mosteiro, A., Cabrera, G., Apolinar, A., Sala, F., Masotto, B., Enseñat, J., Di Somma, A. and Galino, A.P., 2026. Anatomical insights into the peri-trigeminal zone via transorbital, transclival, and retrosigmoid routes: a comparative cadaveric study with surgical implications. *Acta Neurochirurgica*, 168(1), p.53.
25. Sharma, D., Kaul, R. and Agrawal, D., 2025. Morphometric Analysis of Tentorial Orifice and its Anatomical Variations as Relevant to Transtentorial Herniation: A Preliminary Cadaveric Study. *Indian Journal of Neurotrauma*, 22(02), pp.168-172.
26. Campagnaro, L., Boschi, A., Petrella, L., Pisano, A., Capelli, F., Esposito, A., Trabalzini, F., Jean, W.C. and Della Puppa, A., 2026. Quantitative Analysis of the Working Windows for Sitting and Park Bench Positions Through the Retrosigmoid Approach Evaluated in a Cadaver Model. *Operative Neurosurgery*, 30(1), pp.137-146.
27. Amani, V., Doroudi, M. and Alimohammadi, M., 2026. Abducens Nerve Entrapment and Cortical Compression Due to Severe Cranial Hyperostosis: A Cadaveric Case Report.