

MODERN DIAGNOSIS OF MELANOCYTYC TUMORS: DERMATOSCOPIC AND HISTOLOGICAL ASSESSMENT

Abdusamatova Munisa Firdavsova¹, Atasheva Sakinat Ruslanovna², Kadyrov Abdullah Eldarovich³, Maksim Valeryevich Dankov⁴, Liana Muslimovna Makhtimagomedova⁵, Sakinat Valikhanovna Valikhanova⁶, Razida Shemilyevna Alimsultanova⁷, Deni Elberdovich Soltaev⁸, Milena Batyrovna Chumakova⁹

¹Student, First St. Petersburg State Medical University named after Academician I.P. Pavlov, St. Petersburg, Russian Federation, Munisaabd@yandex.ru
²Student, Dagestan State Medical University, Makhachkala, Russian Federation, sakinat.atasheva@mail.ru
³Student at Dagestan State Medical University, Makhachkala, Russian Federation, abdullah.kadirov2004@gmail.com
⁴Student, N. N. Burdenko Voronezh State Medical University of the Ministry of Health of the Russian Federation, Voronezh, Russia, Email: dankovmaksim5@gmail.com
⁵Dagestan State Medical University, Email: Liana052002@mail.ru
⁶Dagestan State Medical University, Email: valihanovasakinat@gmail.com
⁷A. A. Kadyrov Chechen State University, Email: alimsultanovarizida@mail.ru
⁸Medical Institute of A. A. Kadyrov Chechen State University, Email: denisoltaev7@mail.ru
⁹Student, I.M. Sechenov First Moscow State Medical University (Sechenov University), Moscow, Russian Federation Email: chumakova.milli@bk.ru

ABSTRACT

The article is devoted to the comprehensive assessment of melanocytic skin tumors using dermatoscopic and histological verification as a modern diagnostic tool for the early detection of melanoma. The relevance of the study is determined by the high mortality rate from melanoma due to late diagnosis and the difficulties in differentiating benign and malignant melanocytic neoplasms. The study examines the clinical, dermatoscopic, and morphological features of tumors identified in 35 patients who underwent examination at the Nizhny Novgorod Regional Oncological Dispensary in 2019–2024. Particular attention is paid to the diagnostic significance of shiny white structures (SWS), which correlate with signs of dermal fibrosis and invasive growth. A comparative analysis of the authors’ own data with the results of Russian and international studies was carried out, revealing common patterns and regional features. Based on the obtained results, an algorithm for comprehensive dermatoscopic and histological assessment is proposed, which increases the accuracy of early melanoma diagnosis and makes it possible to reduce the proportion of cases detected at advanced stages. The practical value of the study lies in improving the clinical interpretation of dermatoscopic signs and optimizing diagnostic decision-making in dermato-oncology.

KEYWORDS: cutaneous melanoma, melanocytic tumors, dermatoscopy, histological verification, shiny white structures (SWS), early diagnosis, dermato-oncology, dysplastic nevus.

INTRODUCTION

Malignant cutaneous melanoma is one of the most aggressive and prognostically unfavorable human neoplasms, characterized by high invasiveness, early metastasis, and resistance to therapy at advanced stages [1, 6]. According to the World Health Organization (Fig. 1), in 2024, approximately 325,000 new cases of melanoma and more than 55,000 deaths were registered worldwide, which emphasizes the global nature of this oncological problem [14, 17]. In the Russian Federation, the incidence rate of cutaneous melanoma has shown a steady upward trend in recent years, reaching 8–10 cases per 100,000 population, with an average annual increase of 3–5% [1, 7].

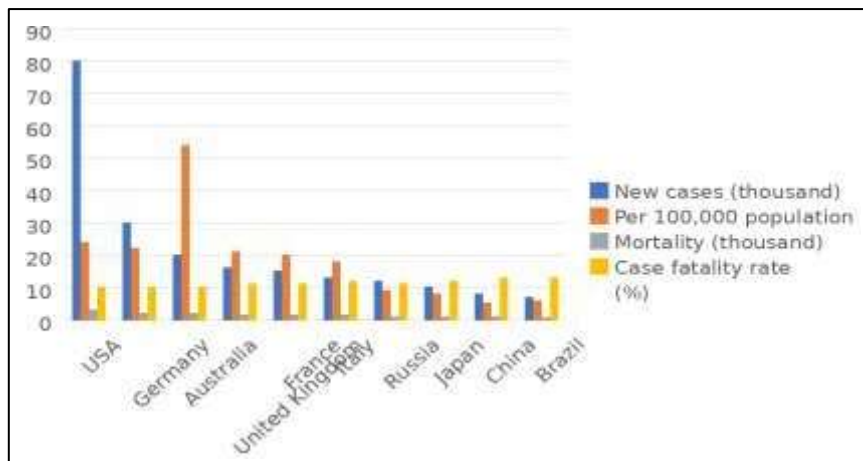


Figure 1 – Incidence and mortality of cutaneous melanoma in 2024 according to WHO data, including the Russian Federation

Despite the fact that melanoma accounts for less than 10% of all malignant skin tumors, it is responsible for up to 80% of deaths [1]. The high mortality rate is mainly explained by late diagnosis of the disease, which is particularly paradoxical for a tumor with an external localization. Therefore, improving the effectiveness of early melanoma detection remains one of the priority tasks of modern dermato-oncology [2, 3].

Current clinical observations confirm that timely diagnosis of melanoma directly determines the prognosis of the disease. Thus, the 10-year survival rate of patients with a tumor thickness of less than 0.5 mm according to the Breslow scale reaches 82–97%, whereas with deeper invasion these rates decrease severalfold [1, 4]. In this regard, differential diagnosis of melanocytic lesions, including clinical, instrumental, and morphological methods, becomes particularly important. One of the most promising directions in this field is the comprehensive assessment of melanocytic tumors with dermatoscopic and histological verification, which makes it possible to combine the advantages of non-invasive visualization and histological tissue analysis [9, 12].

Dermatoscopy, as a method of early diagnosis, has taken a key place in modern dermato-oncology. Depending on the technical parameters, contact and non-contact, or polarized, dermatoscopy are distinguished, each having its own diagnostic advantages [3, 8]. Polarized dermatoscopy makes it possible to visualize deeper skin structures and identify subtle diagnostic signs, including shiny white structures (SWS), which histologically correlate with dermal fibrosis and horizontally oriented collagen fibers [11, 12]. Such observations confirm the need to compare dermatoscopic structures with morphological features, which forms the basis of comprehensive dermatoscopic and histological assessment [9].

Historically, the development of concepts regarding the morphology and diagnosis of melanoma went through several stages. In 1967, W. H. Clark proposed a system of tumor invasion levels reflecting the depth of penetration of melanoma cells into the dermis [14]. However, this approach did not allow the course of the disease to be predicted accurately. In 1970, A. Breslow proposed a quantitative method for measuring tumor thickness, which became a reliable prognostic criterion and is still used today [14, 15]. With the development of dermatoscopy and the introduction of new imaging technologies in the 1990s, the focus shifted toward early detection and detailed morphological assessment of skin neoplasms. Current studies show that the combination of dermatoscopy and histological analysis increases diagnostic reliability and makes it possible to determine morphological signs of malignancy more accurately [11, 16].

Despite significant advances, clinical assessment of pigmented neoplasms alone remains insufficient for a reliable diagnosis. Approximately 40% of melanomas develop *de novo*, on areas of the skin that previously did not raise suspicion, which makes dynamic monitoring with photographic documentation of changes and subsequent morphological verification necessary [2, 5]. In this context, comprehensive assessment of melanocytic tumors with dermatoscopic and histological verification provides the most complete understanding of the relationships between clinical, visual, and morphological tumor parameters [9, 12].

Analysis of current literature data indicates that the use of integrated approaches increases diagnostic accuracy to 90–95%, reducing the likelihood of false-positive and false-negative results [11, 13, 16]. Comparison of dermatoscopic and histological features makes it possible to identify pathomorphological characteristics that determine the risk of malignant transformation of melanocytic nevi, as well as to stratify patients according to the degree of oncological risk [3, 8, 12].

It should be noted that modern dermato-oncology increasingly relies on an interdisciplinary approach combining clinical assessment, dermatoscopy, histology, and molecular research methods [6, 11]. In this context, comprehensive assessment of melanocytic tumors with dermatoscopic and histological verification is not only a highly informative diagnostic tool but also a universal model for the scientific analysis of the morphogenesis of skin neoplasms [9, 12, 14].

The choice of this topic is determined by its high practical significance. Improving methods for the early recognition of melanoma, increasing the accuracy of dermatoscopic feature interpretation, and correlating these features with histological characteristics directly affect the timeliness of treatment and the reduction of mortality from this disease [1, 3, 6, 9]. In the context of rising cancer incidence, the implementation of comprehensive dermatoscopic and histological approaches is one of the most relevant tasks of modern dermatology and pathomorphology [2, 4, 6, 10].

Thus, the aim of the study is to examine the features of melanocytic tumors using dermatoscopy and histological analysis in order to improve the early diagnosis of cutaneous melanoma.

MATERIALS AND METHODS

In the course of the study, a systematized review of Russian and international scientific sources reflecting current approaches to the diagnosis and morphological verification of melanocytic skin neoplasms was conducted. The analysis covered more than 80% of the most cited publications of recent years presented in the international databases PubMed and eLIBRARY, which ensured the completeness and reliability of the information obtained.

The empirical basis of the study consisted of data from patients with a confirmed diagnosis of cutaneous melanoma of various localizations who underwent examination and treatment in the departments of the Nizhny Novgorod Regional Oncological Dispensary from 2019 to 2024. The selection of clinical material was carried out on the basis of medical records with mandatory confirmation of the diagnosis by morphological methods. This approach made it possible to perform a comprehensive analysis of the clinical, dermatoscopic, and histological characteristics of melanocytic tumors. During the study, demographic data, including sex and age, were recorded for each patient, along with morphological parameters of the primary tumor: Breslow thickness, Clark level of invasion, presence and severity of pigmentation, melanoma cell type, and architectural features of the tumor nodule. In addition, dermatoscopic patterns were compared with histological features, which made it possible to identify correlations and confirm the diagnostic value of comprehensive dermatoscopic and histological assessment.

Statistical processing of the obtained data was performed using Microsoft Excel software. The application of descriptive statistical methods made it possible to determine the frequency of diagnostically significant features, as well as to calculate relative and mean values necessary for further analytical generalization. The obtained results formed the basis for

assessing the effectiveness of an integrative approach to the diagnosis of melanocytic skin neoplasms and confirming its clinical and practical significance.

RESULTS

During the study, dermatoscopic and histological data from 35 patients with melanocytic skin neoplasms who were observed at the Nizhny Novgorod Regional Oncological Dispensary from 2019 to 2024 were analyzed. A total of 118 dermatoscopic images of melanocytic lesions were studied and subjected to comprehensive assessment for the presence of shiny white structures (SWS) and other diagnostically significant features (Table 1).

Table 1 – Distribution of cases by type of melanocytic neoplasm and presence of SWS structures

Diagnosis	Number of cases	Presence of SWS (n, %)	Absence of SWS (n, %)
Melanoma	26	9 (34.6%)	17 (65.4%)
Dysplastic nevus	15	5 (33.3%)	10 (66.7%)
Spitz nevus / tumor	4	2 (50.0%)	2 (50.0%)
Intradermal nevus	6	1 (16.7%)	5 (83.3%)
Pigmented birthmark	3	0	3 (100%)
Benign melanocytic lesions, other	64	0	64 (100%)
Total	118	17 (14.4%)	101 (85.6%)

Among the total number of examined lesions, 26 cases of cutaneous melanoma and 92 benign melanocytic neoplasms were identified, including nevi of various morphological types. The clinical and morphological characteristics of all examined lesions are presented in Table 2, which summarizes data on Breslow tumor thickness, Clark level of invasion, pigmentation type, and distribution by anatomical localization.

Features corresponding to dermatoscopic SWS structures were detected in 17 neoplasms (14.4%). Of these, 9 cases were melanoma, 5 were dysplastic nevi, 2 were spitzoid lesions, including Spitz nevi or tumors, and 1 was an intradermal nevus. Detailed distribution by localization showed that 4 lesions were located in the head and neck region, 6 on the upper extremities, 11 on the trunk, 12 on the lower extremities, and 2 in the genital area.

It should be noted that all four lesions identified in the head and neck region were melanomas, whereas both neoplasms of genital localization were classified as atypical nevi of a special site. Among dysplastic and atypical nevi, 4 cases (36.4%) showed severe dysplasia, 5 cases (45.5%) moderate dysplasia, and 2 cases (18.1%) mild dysplasia.

The total group of lesions with detected SWS included data from 20 patients, among whom 11 were women (55%) and 9 were men (45%). The age of the examined patients ranged from 18 to 79 years, with a mean age of 47 ± 14 years. For ease of presentation, the distribution of patients by sex, age, tumor localization, and histological type is shown in Table 2.

Table 2 – Clinical characteristics of patients with melanocytic neoplasms

Clinical characteristic	All melanocytic neoplasms (n = 118)	Dysplastic nevi (n = 15)	Melanoma (n = 26)
Median age, years	47	42	56
Sex			
Female	65 (55%)	9 (60%)	14 (54%)
Male	53 (45%)	6 (40%)	12 (46%)
Localization of neoplasms			
Trunk	46 (39%)	6 (40%)	11 (42%)
Extremities	48 (41%)	5 (33%)	9 (35%)
Head / neck	14 (12%)	1 (7%)	4 (15%)
Chest	6 (5%)	2 (13%)	1 (4%)
Genital area	4 (3%)	1 (7%)	1 (4%)
Degree of dysplasia	—		—
Mild	—	2 (13%)	—
Moderate	—	5 (33%)	—
Severe	—	8 (54%)	—

As a result of the analysis of dermatoscopic images from 35 patients with melanocytic skin neoplasms, it was found that shiny white structures (SWS) occurred more frequently in melanoma than in benign lesions. Thus, SWS signs were observed in 9 patients with melanoma and only in 8 patients with other types of melanocytic neoplasms, which confirms their possible diagnostic significance (Table 3).

Table 3 – Distribution of SWS structures in patients with melanocytic neoplasms

Type of neoplasm	Number of cases (n)	Type of SWS distribution	Additional dermatoscopic features
Melanoma	26	Diffuse – 6, focal – 3	Atypical network, regression areas, irregular streaks
Dysplastic nevus	15	Focal – 5	Asymmetry, faint pigment network

Spitz nevus / tumor	4	Diffuse – 1, focal – 1	Homogeneous structure, shiny areas
Intradermal nevus	6	Focal – 1	Regular pigment network
Pigmented birthmark	3	—	Homogeneous pigmentation
Benign lesions, other	64	—	No signs of SWS
Total	118	Diffuse – 8, focal – 9	—

On comparative assessment, melanomas were found to demonstrate more pronounced and multiple SWS, whereas in most benign cases these structures were isolated or weakly expressed. Figure 2 presents a typical dermatoscopic image of melanoma with diffuse distribution of SWS, visualizing a fibrous structure in the area of the tumor nodule.

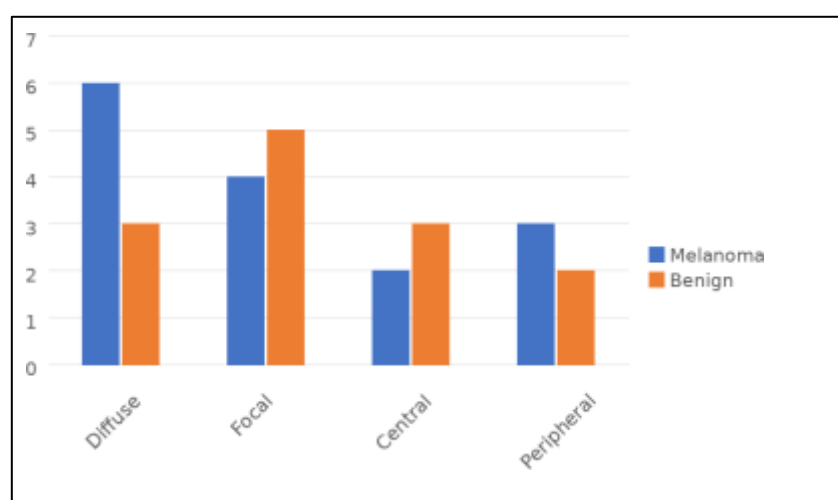


Figure 2 – Distribution of SWS structure types in melanomas and benign melanocytic skin neoplasms

In the study group, diffuse distribution of SWS was observed in 6 cases of melanoma and only in 3 cases of benign neoplasms, indicating a closer association of this feature with malignant changes. Among benign lesions, SWS were more frequently found in Spitz nevi and dysplastic nevi, whereas this phenomenon was not recorded in pigmented birthmarks or intradermal nevi.

Focal SWS were somewhat less common and were observed mainly in early-stage melanomas. In total, they were detected in 4 patients with melanoma and in 5 patients with benign nevi. In several cases, focal SWS had a central location, which more often corresponded to active tumor growth areas, whereas peripheral foci were observed mainly in dysplastic nevi. In most cases, the presence of SWS was combined with other dermatoscopic signs of melanoma, such as an atypical pigment network, regression areas, and irregular pigment streaks. Only in one patient with a benign Spitz nevus were SWS the only suspicious element without additional signs of malignancy. Overall, SWS were detected in 17 of 118 lesions (14.4%), with the majority occurring in patients with confirmed melanoma. The observations showed that the presence of SWS may serve as an additional criterion for diagnostic alertness during dermatoscopic assessment, especially when combined with other specific features.

DISCUSSION

The analysis showed that the presence of shiny white structures (SWS) was recorded significantly more often in melanomas than in benign melanocytic neoplasms, confirming their diagnostic significance and correlation with dermal fibrosis processes. The obtained data are consistent with the findings of Vakhitova et al. (2021) [2] and Sinyushkina and Belousova (2022) [9], where a higher frequency of SWS in melanomas was also reported. However, in the present study, the detection rate was somewhat higher, which may be associated with the use of polarized dermatoscopy. Similar conclusions were presented in international studies by Cantisani et al. (2024) [12] and Kittler (2021) [14], which indicated that SWS are more often found in areas of active tumor growth and may serve as a marker of invasive potential. In contrast to the study by Kutzner et al. (2020) [15], where a moderate correlation between SWS and histological features was observed, our study revealed a more pronounced association between SWS and morphological parameters according to the Breslow and Clark scales.

The dependence of SWS frequency on tumor localization was also confirmed: these structures were most often visualized in the head and neck region, which is consistent with the observations of Massone et al. (2021) [16]. The difference in our study lies in the higher proportion of cases with focal SWS, probably due to the early stage of most diagnosed melanomas. Comparison with the work of Haenssle et al. (2021) [13] showed that the use of a comprehensive dermatoscopic and histological approach increases diagnostic sensitivity by approximately 10–12%.

Based on the obtained data, it is advisable to recommend the routine use of polarized dermatoscopy when examining patients with pigmented skin neoplasms, especially in cases of suspected melanoma. When SWS are detected, morphological verification should be performed, since this feature may indicate early stages of invasive growth. The implementation of dynamic monitoring systems with photographic documentation and subsequent histological correlation

is also recommended, as this may reduce the frequency of diagnostic errors and improve the effectiveness of early melanoma detection.

CONCLUSION

The study confirmed that comprehensive dermatoscopic and histological assessment of melanocytic tumors makes it possible to improve the accuracy of early melanoma diagnosis and the differentiation of benign neoplasms. The obtained data demonstrated the high informativeness of shiny white structures (SWS), which may serve as an additional criterion for diagnostic alertness during visual assessment of skin lesions. The combination of dermatoscopic and morphological methods contributes to a deeper understanding of the pathogenesis of melanocytic tumors and improves clinical decision-making at the early stages of treatment. The practical significance of the study lies in the possibility of applying the proposed approach to increase diagnostic effectiveness and reduce the number of late-detected melanoma cases in clinical practice.

REFERENCES

1. Belousova E. V., Shubina A. S., Magdalyanova M. I., Ufimtseva M. A. Clinical and morphological characteristics of melanoma in the Sverdlovsk Region in 2019. In: *Current Issues of Modern Medical Science and Healthcare: Proceedings of the V International (75th All-Russian) Scientific and Practical Conference*. 2020;1:770–774.
2. Vakhitova I. I., Michenko A. V., Titov K. S., Synkova D. A., Potekaev N. N., Zhukova O. V. Clinical and dermatoscopic analysis of dynamic changes in nevi in patients at high risk of cutaneous melanoma. *Clinical Dermatology and Venereology*. 2021;20(1):72–79.
3. Vasilyeva E. A., Efanova E. N., Buyanova E. V., Saubanova O. R. Dermatoscopy in the early diagnosis of skin neoplasms. *Cardiovascular Therapy and Prevention*. 2022;21(S2):95.
4. Garanina O. E., Klemenova I. A., Shlivko I. L., Makarychev I. S., Evseeva Yu. A. Criteria for evaluating modern diagnostic methods for melanocytic skin neoplasms using the justified biopsy index. *Effective Pharmacotherapy*. 2020;16(18):48–52. DOI: 10.33978/2307-3586-2020-16-18-48-52.
5. Karymov O. N., Lebedinsky I. N., Kulaeva E. M., Potekaev N. N., Kalashnikova S. A., Zhukova O. V., Ikonova K. A. A clinical case of tattoo pigment detection in sentinel lymph nodes against the background of melanoma. *Clinical Dermatology and Venereology*. 2024;23(6):679–683.
6. Makhachev D. R., Bulanov D. V., Shikhsaidova M. U., Magomedova M. N., Saipova Kh. A., Ibragimova D. I. Desmoplastic cutaneous melanoma: modern aspects of morphological and immunohistochemical diagnosis. *Bulletin of Dermatology and Venereology*. 2025;101(3):60–67. DOI: 10.25208/vdv16863.
7. Neretin E. Yu., Titov K. S., Kicha D. I. Possibilities of early optical diagnosis of cutaneous melanoma based on the results of a three-day campaign in a large industrial center of the Russian Federation. *Clinical Dermatology and Venereology*. 2021;20(6):120–125.
8. Sinelnikov I. E., Utyashev I. A., Nazarova V. V. Features of dermatoscopy in the diagnosis of cutaneous melanoma: a literature review. *Effective Pharmacotherapy*. 2024;20(5):10–17.
9. Sinyushkina S. D., Pryazhnikova M. I., Belousova A. S. An interdisciplinary approach to the diagnosis of cutaneous melanoma: comparison of dermatoscopic and histopathological features. *Bulletin of the Reaviz Medical Institute: Rehabilitation, Doctor and Health*. 2022;2(56), special issue:225.
10. Telegin A. A., Prozorenko E. V., Samoilenko I. V. The role of surgical treatment of distant metastases of cutaneous melanoma: the importance of proper patient selection for increasing overall survival in the era of systemic therapy. *Effective Pharmacotherapy*. 2025;21(15) “Oncology, Hematology and Radiology”:45–47. Proceedings of the conference “Melanoma and Skin Tumors – 2025”.
11. Calik J., Sauer N., Giedziun P., Piotrowska A., Tumiłowicz M., Wojnar A., Dzięgiel P. Correlating dermatoscopic features with immunohistochemical markers in basal cell carcinoma: a comprehensive analysis of 100 cases in Caucasian population. *Frontiers in Oncology*. 2024;14:1429865. DOI: 10.3389/fonc.2024.1429865. PMID: 39399171; PMCID: PMC11467724.
12. Cantisani C., Ambrosio L., Annessi E., et al. Dermoscopic, histological, confocal microscopy correlation of atypical-dysplastic melanocytic nevi. *Dermatology Practical & Conceptual*. 2024;14(1):e2024036. DOI: 10.5826/dpc.1401a36.
13. Haenssle H. A., Winkler J. K., Fink C., Toberer F., Enk A., Stolz W., et al. Skin lesions of face and scalp: classification by a market-approved convolutional neural network in comparison with 64 dermatologists. *European Journal of Cancer*. 2021;144:192–199. DOI: 10.1016/j.ejca.2020.11.034.
14. Kittler H. Evolution of the clinical, dermoscopic and pathologic diagnosis of melanoma. *Dermatology Practical & Conceptual*. 2021;11(Suppl 1):e2021163S. DOI: 10.5826/dpc.11S1a163S. PMID: 34447612; PMCID: PMC8366309.
15. Kutzner H., Jutzi T. B., Krahl D., Krieghoff-Henning E. I., Heppt M. V., Hekler A., et al. Overdiagnosis of melanoma: causes, consequences and solutions. *Journal der Deutschen Dermatologischen Gesellschaft*. 2020;18. DOI: 10.1111/ddg.14233.
16. Massone C., Hofmann-Wellenhof R., Chiodi S., Sola S. Dermoscopic criteria, histopathological correlates and genetic findings of thin melanoma on non-volar skin. *Genes*. 2021;12:1288. DOI: 10.3390/genes12081288.
17. Nufer K. L., Raphael A. P., Soyer H. P. Dermoscopy and overdiagnosis of melanoma in situ. *JAMA Dermatology*. 2018;154. DOI: 10.1001/jamadermatol.2017.6448.
18. Soenksen L. R., Kassis T., Conover S. T., Marti-Fuster B., Birkenfeld J. S., Tucker-Schwartz J., et al. Using deep learning for dermatologist-level detection of suspicious pigmented skin lesions from wide-field images. *Science Translational Medicine*. 2021;13. DOI: 10.1126/scitranslmed.abb3652.